Case 17

Publication consent has been granted

Born 19.03.1938, died 16.4.21

W 83 1xBioNT 10 d

17.1 History of death and vaccination.

1 vaccination Comirnaty (Biontech) on 6.4.21, death 10 days afterwards

Died on 16.4.21. Found dead by her neighbor in her bedroom.

17.2 Medical history.

- Known high blood pressure.
- Family doctor: 5 years not with GP, 29.3. RR light -> adjustment
- All findings normal, "fit and mentally up to date". According to the neighbor, leg vein thrombosis.

Falling calotte fracture/brain hemorrhage => Question Stroke from inside or fall?

Autopsy Results

Institution #1

- The XXXX forensic medicine department informed the public prosecutor's office by telephone that the death may be related to thrombosis, which could be the result of vaccination.

- The determination of specific antibodies (PF 4 / heparin complex) commissioned.

Institution #2

17.3 Light microscopic consultative examination

- Heparin/PF4-specific ELISA: Negative for anti-PF4 heparin antibody
- HIPA test: Negative PIPA test: Negative
- Institute's assessment: No evidence of heparin-induced thrombocytopenia (type 2) or to a SARS-CoV-2 vaccine (Astra Zeneca Covid 19) induced immunothrombotic thrombocytopenia (VITT). The Vaxzevria vaccine can lead to the formation of platelets of activated antibodies against platelet factor 4 (PF4) and activation of the blood platelets with clumping and platelet deficiency. Such anti-PF4 antibodies were not found).
- Softening of the brain in the sense of a stroke, which could be fatal.4x3x2 fresh softening of the left frontal brain.
- Black-red hemorrhage into the scalp of the right forehead.
- High-grade sclerosis of the basal cerebral arteries and the large coronary arteries.
- Smallest Left calf vein thrombosis.
- Slit-shaped foramen ovale.

17.4 Institution #3 Prof. Burkhardt, Prof. Lang, Mörz

1 Spleen:

- Extensive onion-skin phenomenon of the vessels, texture disturbance up to Follicular intrusion.
- Black-colored foreign material, probably not birefringent Preparation artifact (formalin).

- EvG: Confirmation of the onion skin name
- Congo red: positive staining of hyaline vascular inclusions
- Spike S1: negative

2,3,6,7,12,13,15 Heart:

- Median necrosis of the Coronary artery without significant inflammation.
- Cardiac hemosiderin deposition as an indication of intravital dissection bleeding.
- Minimal inflammatory reaction at the vasa vasorum (+).
- 7-EvG: focal destruction of the wall, a smaller intramural artery in particular of the elastic lamellae. Coronary artery branch without significant wall destruction
- 2-EvG: like 7 only better quality for photo documentation
- 2-Congo red: Non-specific staining of the myocytes.
- 2-spike S1: Weak spike marking in the area of the myocardial fibers. Isolated endothelia and myofibroblasts positive for spike
- 2-Nucleocapsid: Negative. Especially endothelia and myofibroblasts positive for
- Cardiac muscle regular.
- Lymphocytic endothelitis in the intramural vessel. ++.
- In the sectional plane, small pieces of stained black foreign material in small predominantly perivascular vacuoles. Weakly birefringent (inorganic material, no formalin pigment).

4 Brain: No significant findings

5,14,17,19 Lungs:

- Small nodular, lymphocytic infiltrates, emphysema.
- Anthracosis (age-appropriate).
- Strangely, the foreign material found in other tissues is not present in the lung preparations.

8.16 Liver:

- Vascular loosening with inflammatory lymphocytic infiltrates in the veins liver stroma.
- Stained black foreign material in small vacuoles.
- Block 16: CD 31 and CD 68

9.11 Kidney: Isolated lymphocytic infiltrates in the cortical interstitium

10 Transversely Striated musculature:

- Focal lymphocytic infiltrates between the muscle fibers (+).
- Stain-like black colored foreign material perivascular, weakly double refractive (inorganic material, not formalin pigment).
- Muscle tissue has negative iron staining (block 10).

18 Adrenal gland:

- Peri-adrenal adipose tissue of the adrenal gland: Small fibrous black tissue
- Foreign material intravacuolar (or in fat cells).
- Block 22 (adrenal gland) contains the stained black foreign material even intravascularly and perivascularly in the adrenal tissue.

20 Dura mater? Block 20 ECG

21 Thyroid gland: No significant findings

Brain: No significant findings

Cerebellum: No significant findings

Brain:

C) Medulla oblongata. Marginal lymphocytic perivascular infiltrates.

D) Gyrus frontalis superior left and cingulum right subarachnoid blood vessels with clumped erythrocytes (thrombus).

- Increased cell accumulation on internal walls (immunohistochemical differentiation)
- Focal lymphocytic endothelial swellings ++ ECG, CD3, CD63

E) Cingulum right, Perivascular lymphocytosis intracerebral (not subarachnoid)

F) Right basal ganglia, Perivascular lymphocytosis TOE

G) Hippocampus right Mild perivascular lymphocytosis (+)

H) Hippocampus left Mild perivascular lymphocytosis (+)

17.4 Interpretation. In our pathohistologic examinations we found in brain tissues perivascular lymphocytic inflammation, sometimes with endothelial swelling. Vascular damage were found in various organs, including in the coronary vessels in the form of median necrosis and in the spleen in the form of pronounced "onion skin-like" textural disturbances of the splenic artery walls.

The blackish-brown, grainy skin that we repeatedly find in people who have died after vaccination, previously unidentified "foreign materials" were found in the spleen, adrenal gland, heart, liver and skeletal muscle, but not in the lungs.

There appears to be a connection between the deaths and the vaccination.

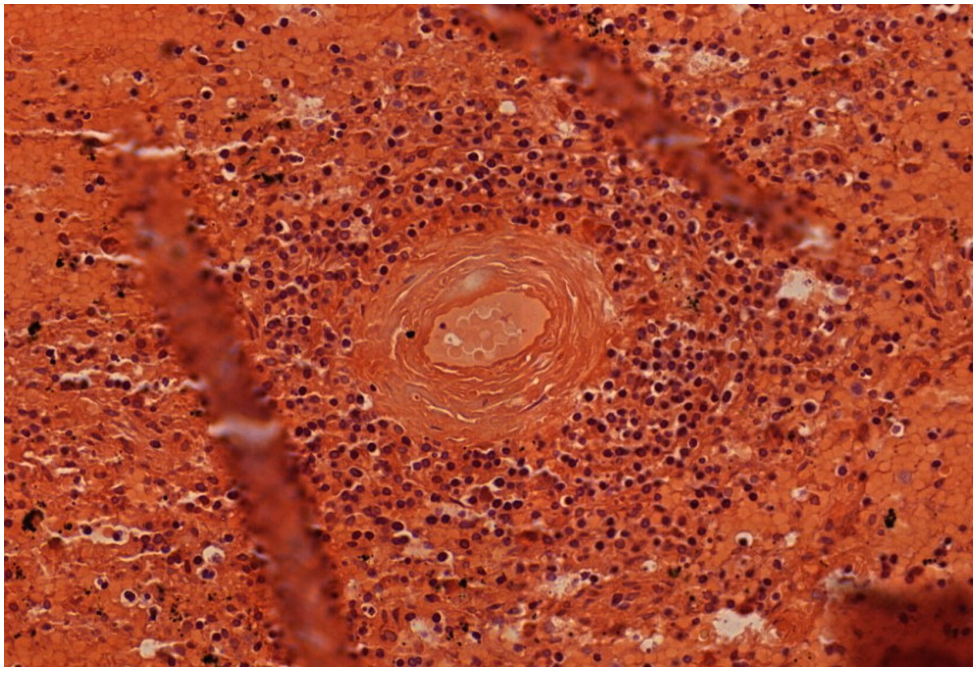

17-1-Amyloid-Spleen 972

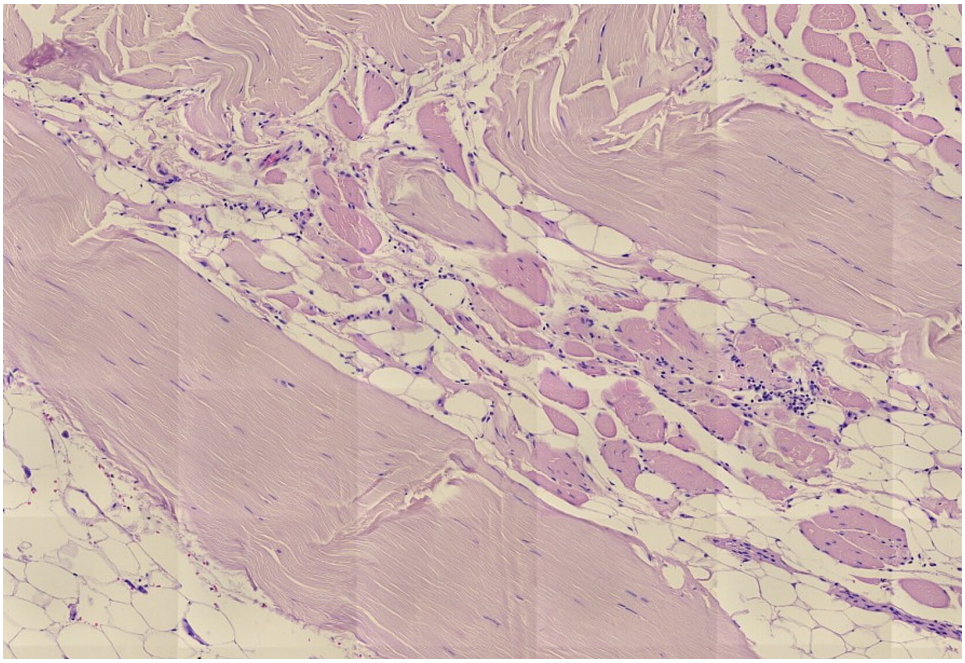

17-10-Heart-1-a

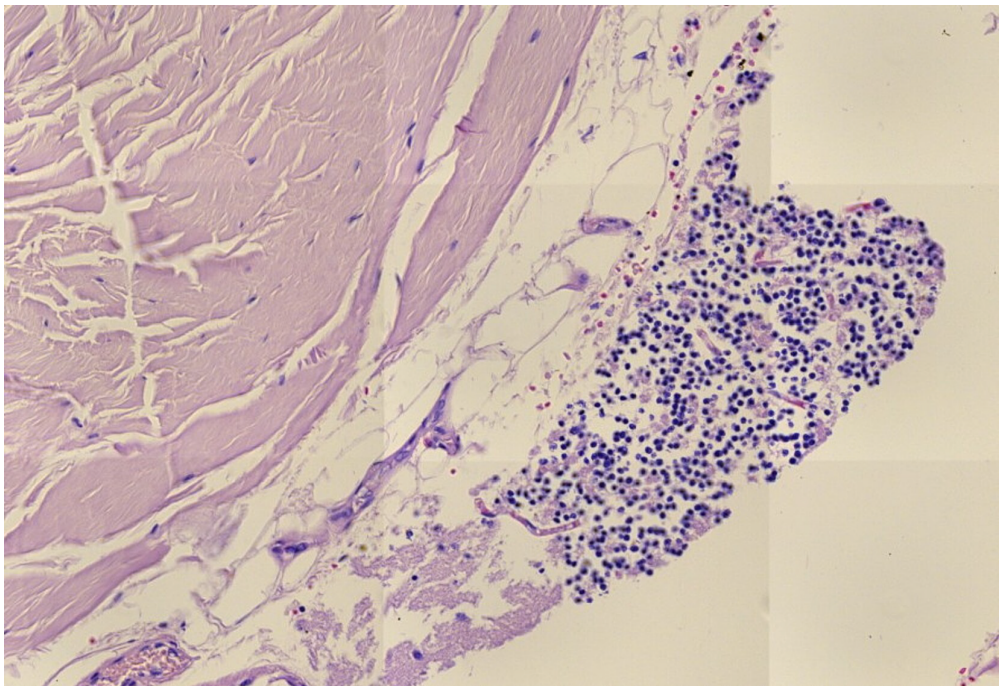

17-10-Heart-1 974

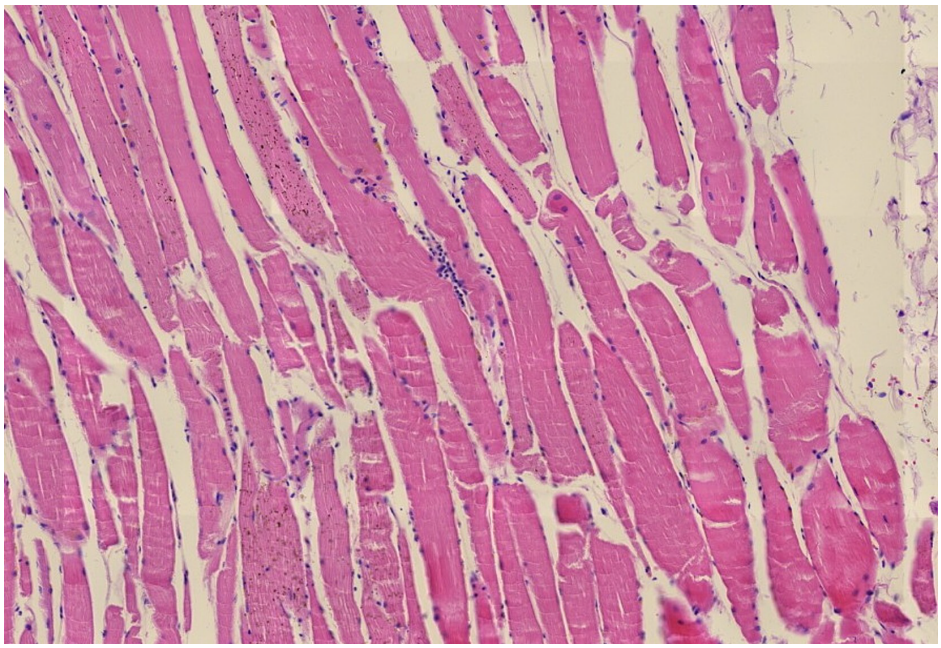

17-10-Heart-a 975

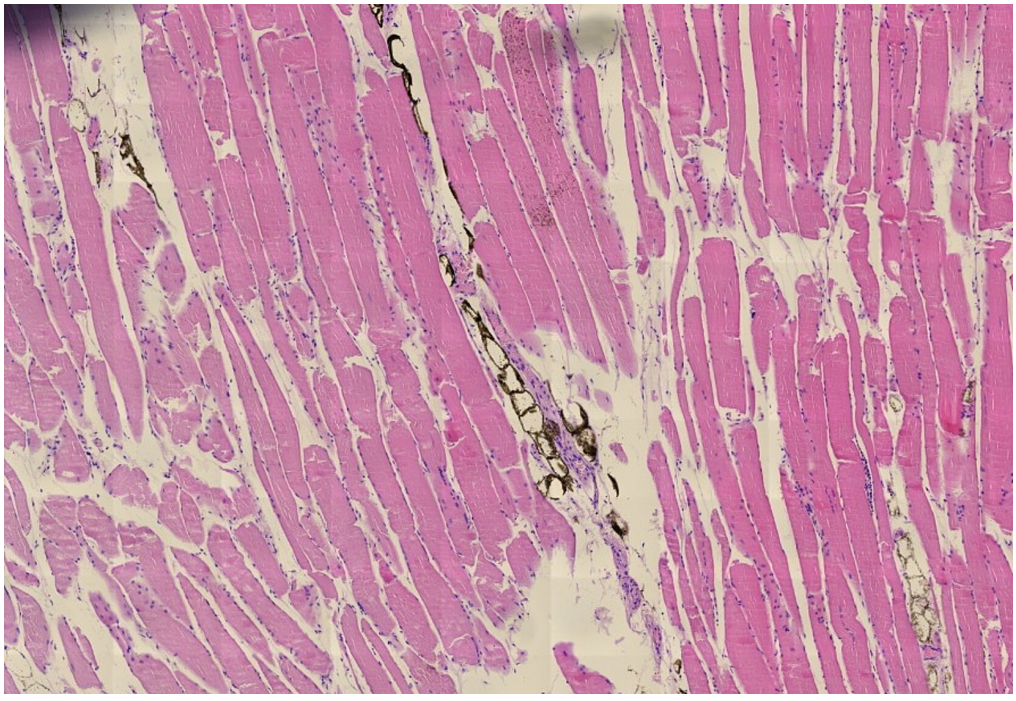

17-10-Heart-aa 976

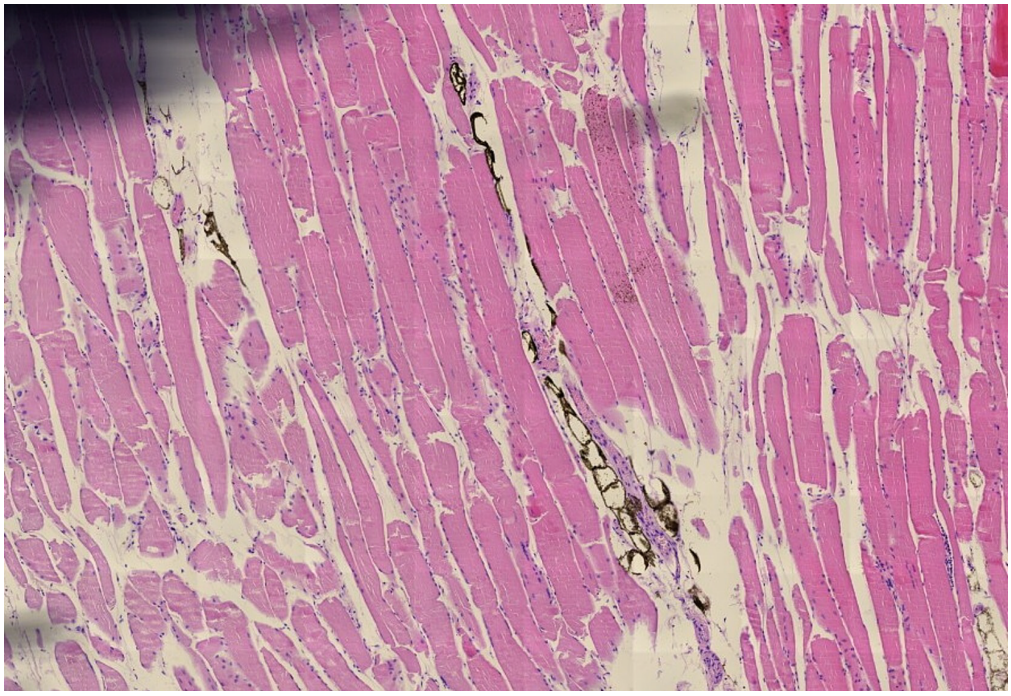

17-10-Heart 977

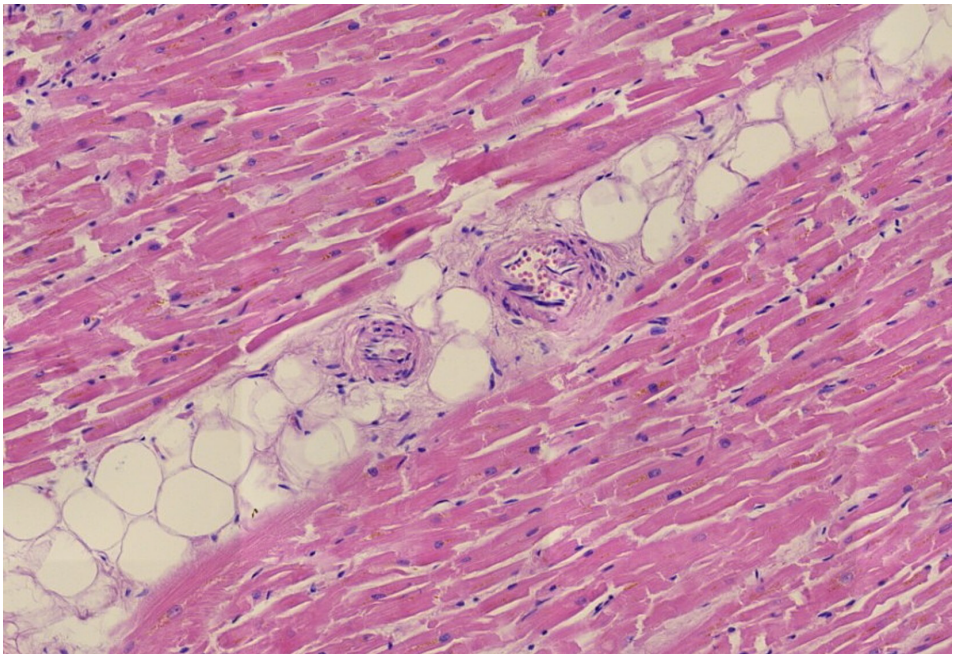

17-12-Heart 978

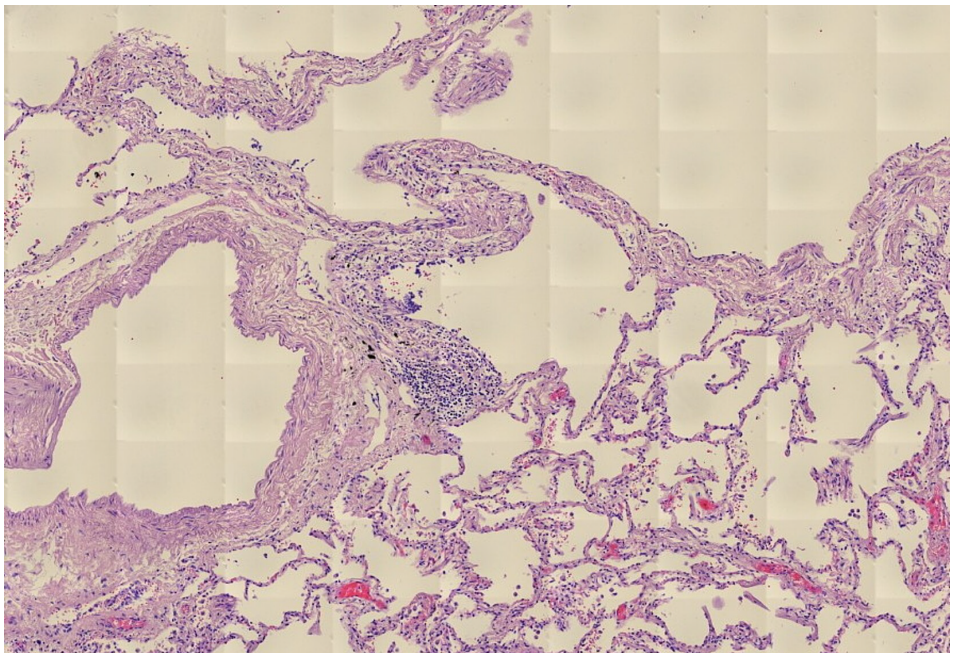

17-14-Lung

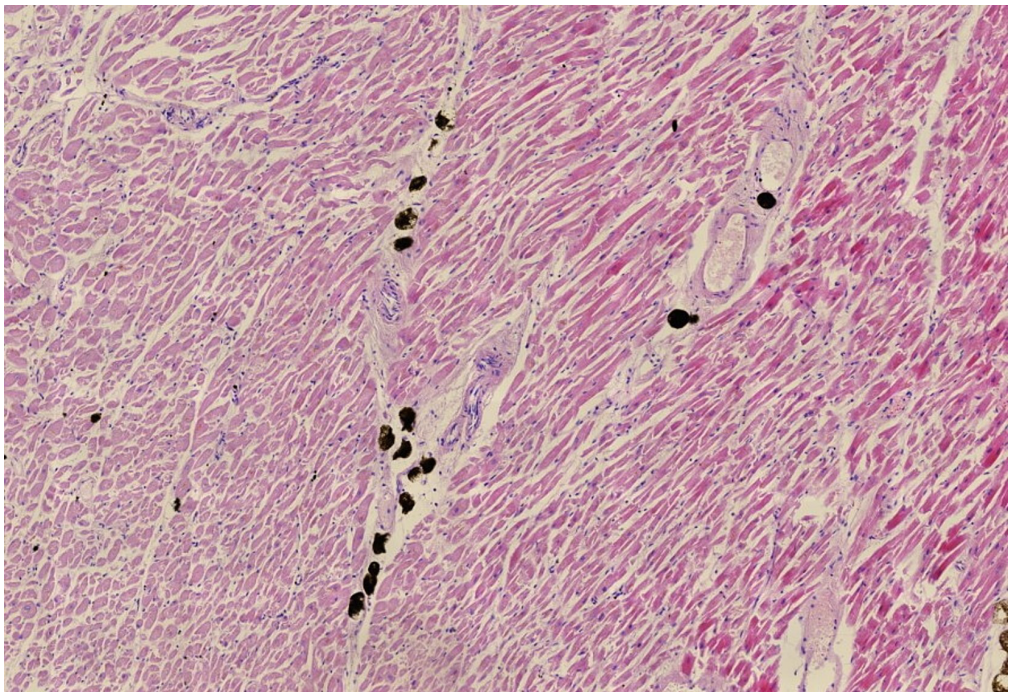

17-15-Heart-a

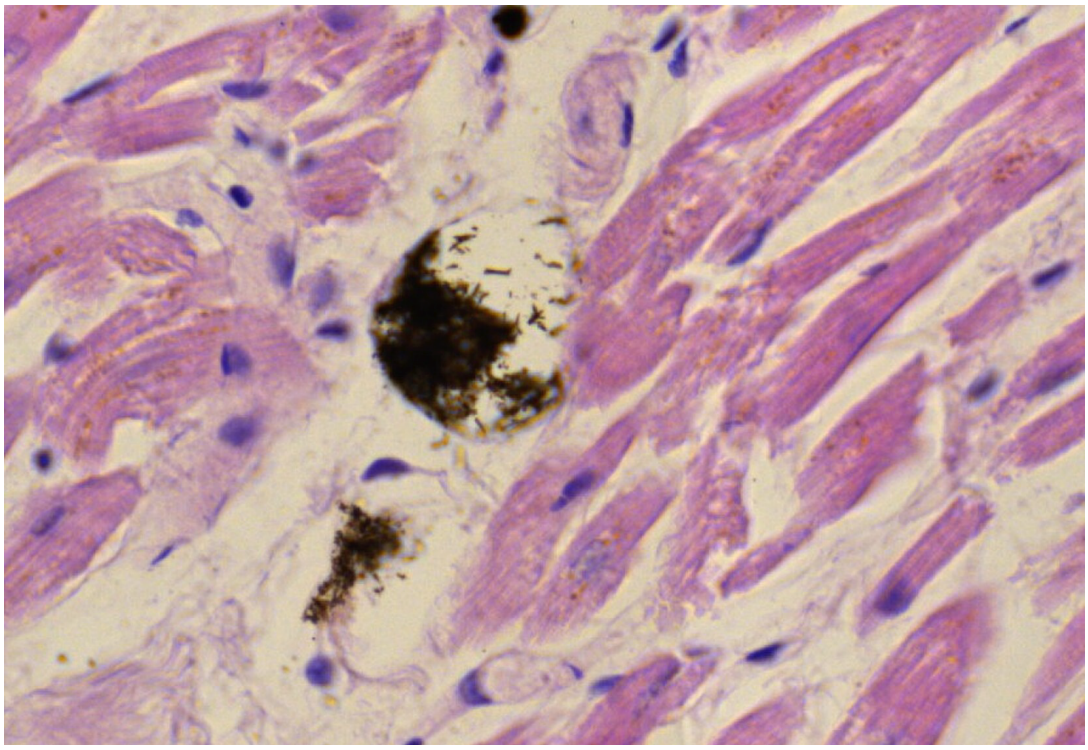

17-15-Heart-b 981

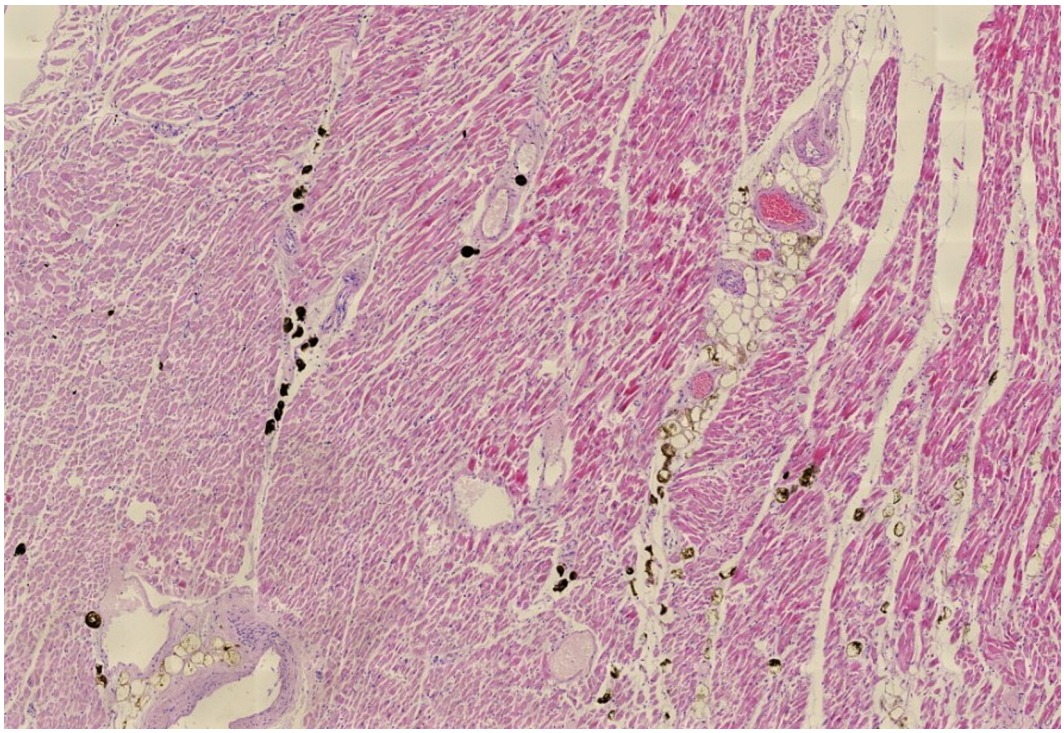

17-15-Heart

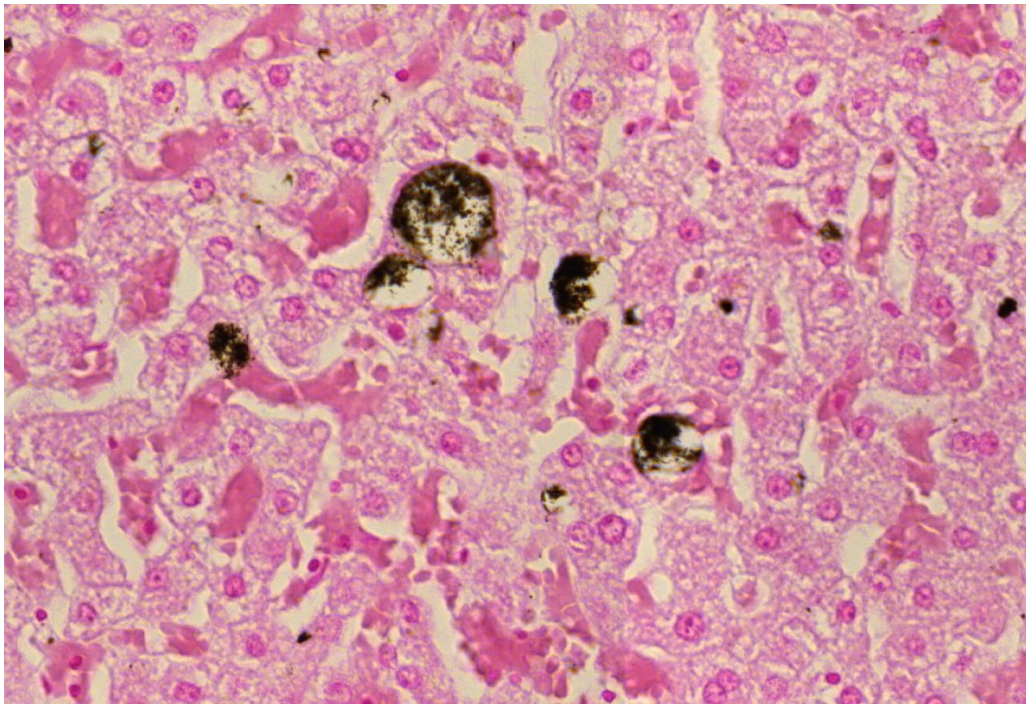

17-16-Liver-a

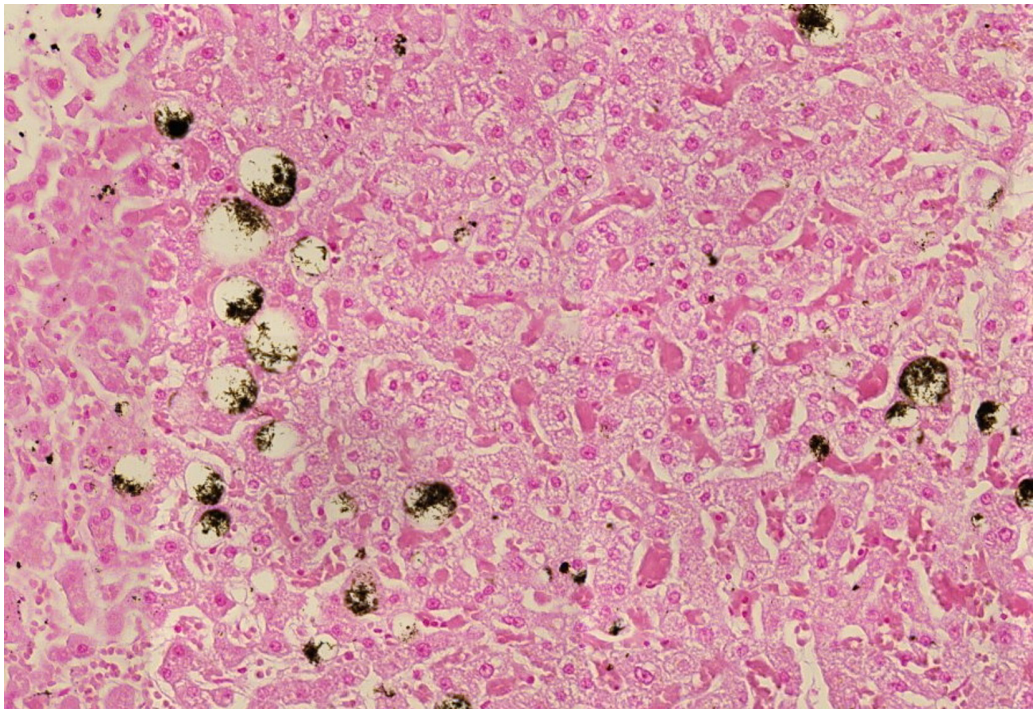

17-16-Liver

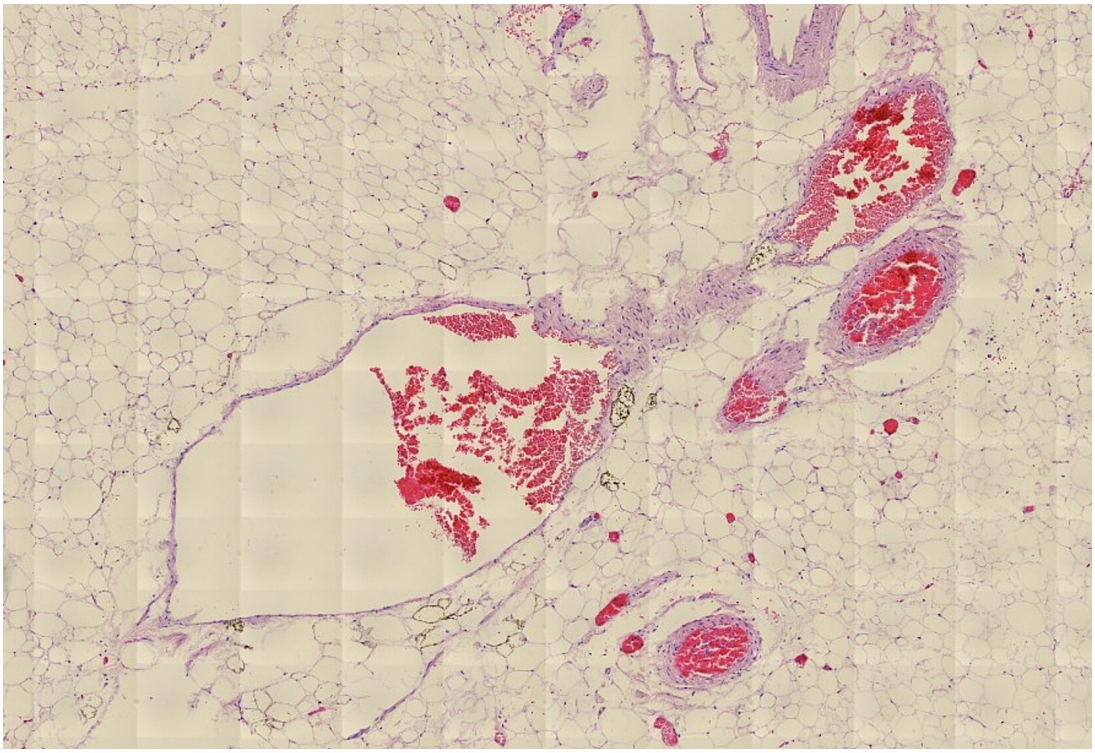

17-18-NN 98

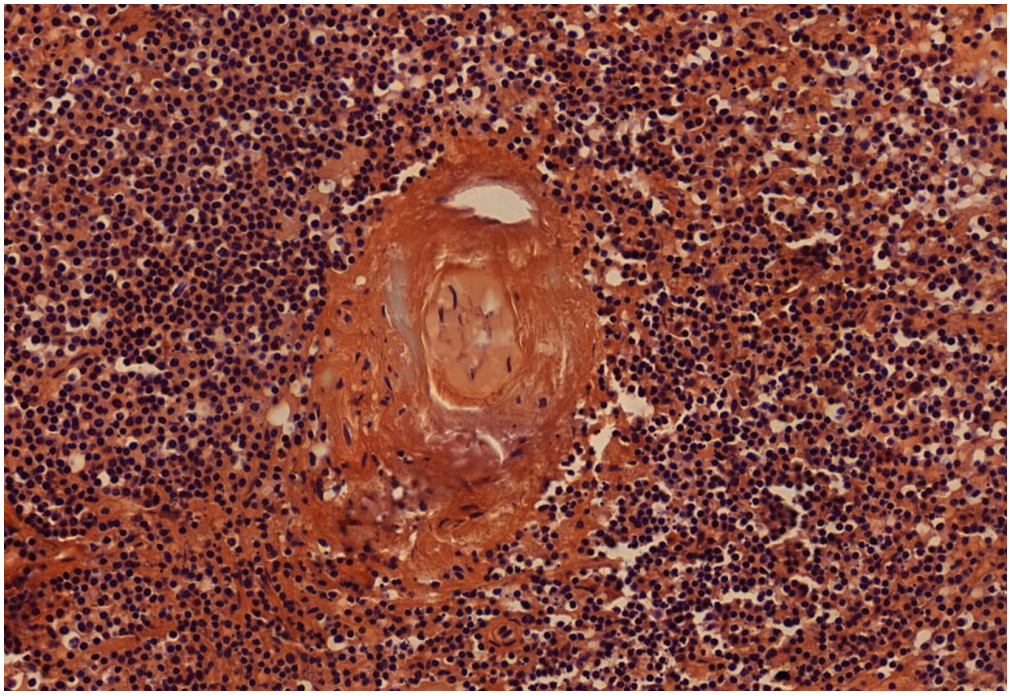

17-2-Amyloid-Spleen-a

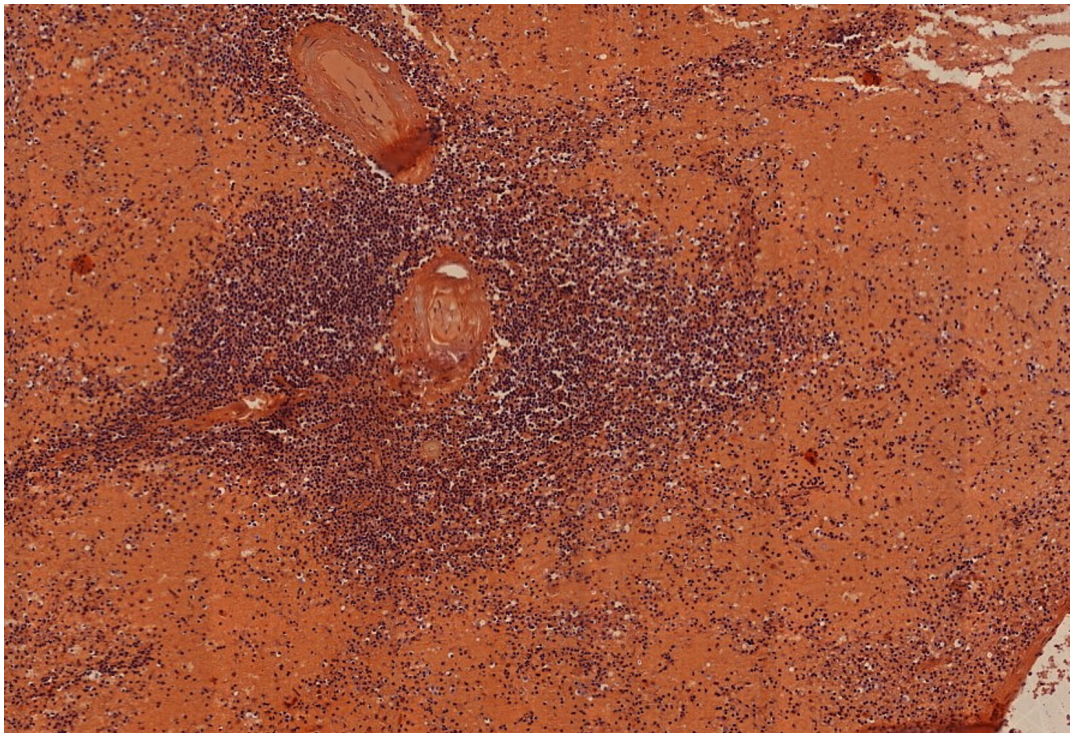

17-2-Amyloid-Spleen

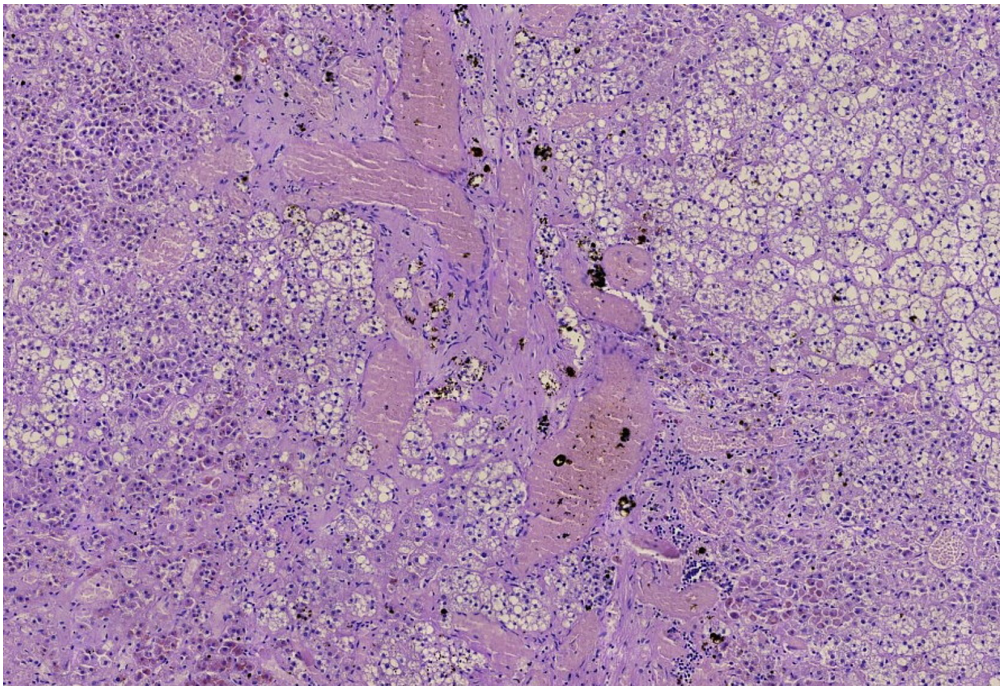

17-22-NN

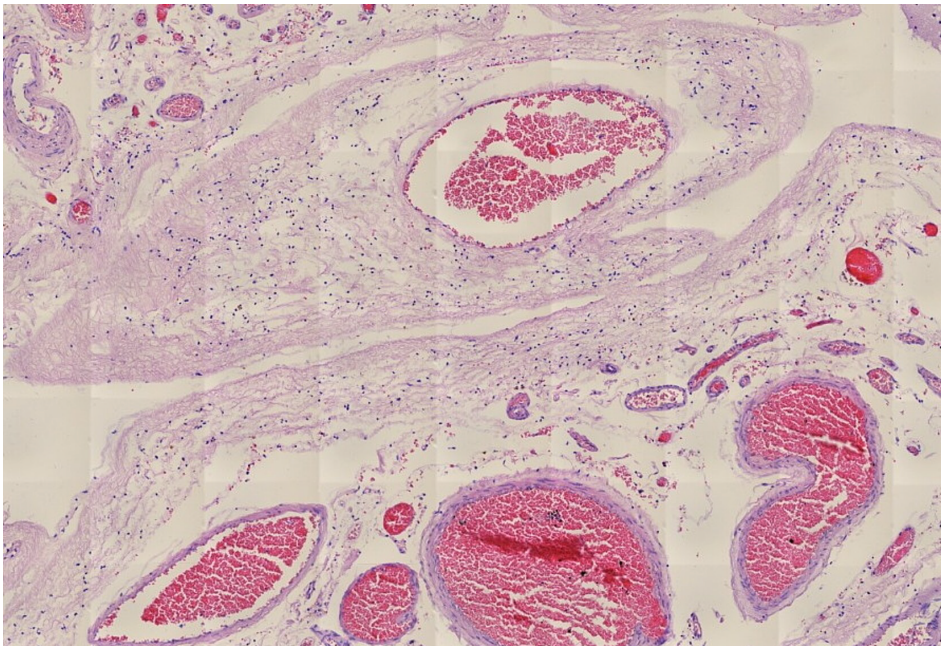

17-28-Brain-a

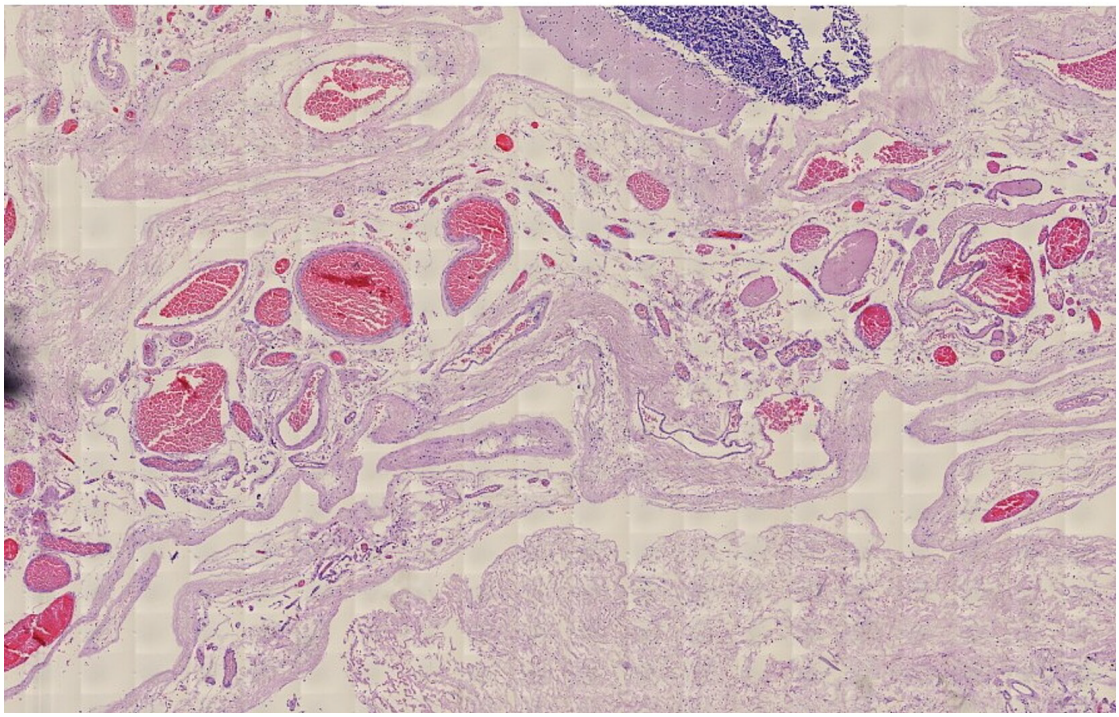

17-28-Brain 990

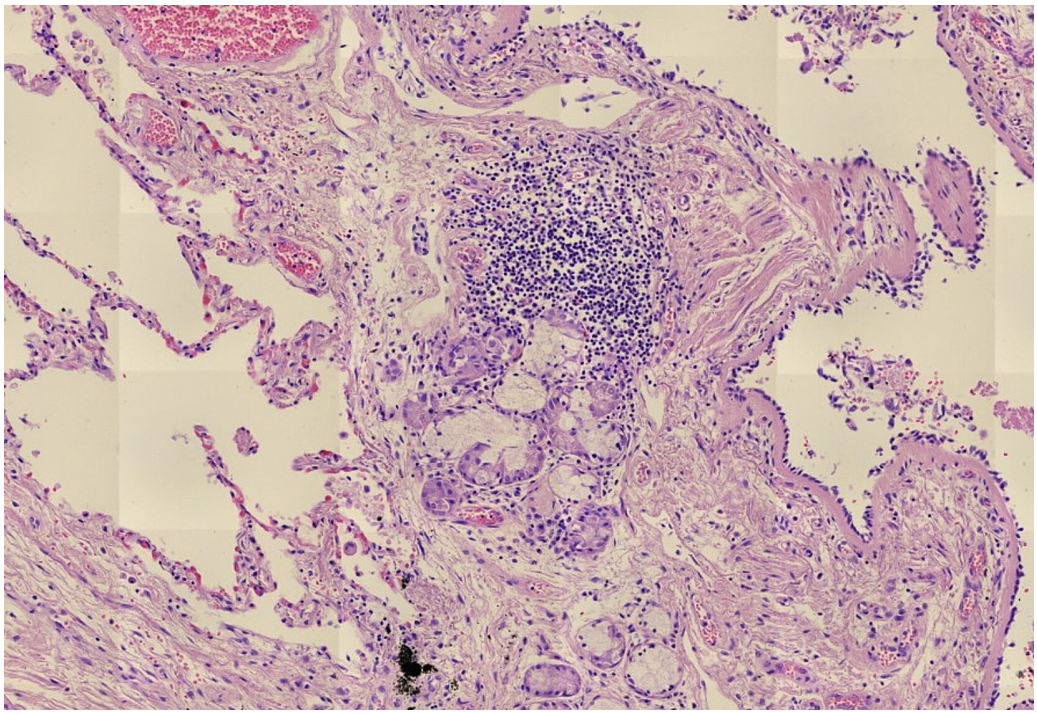

17-5-Lung

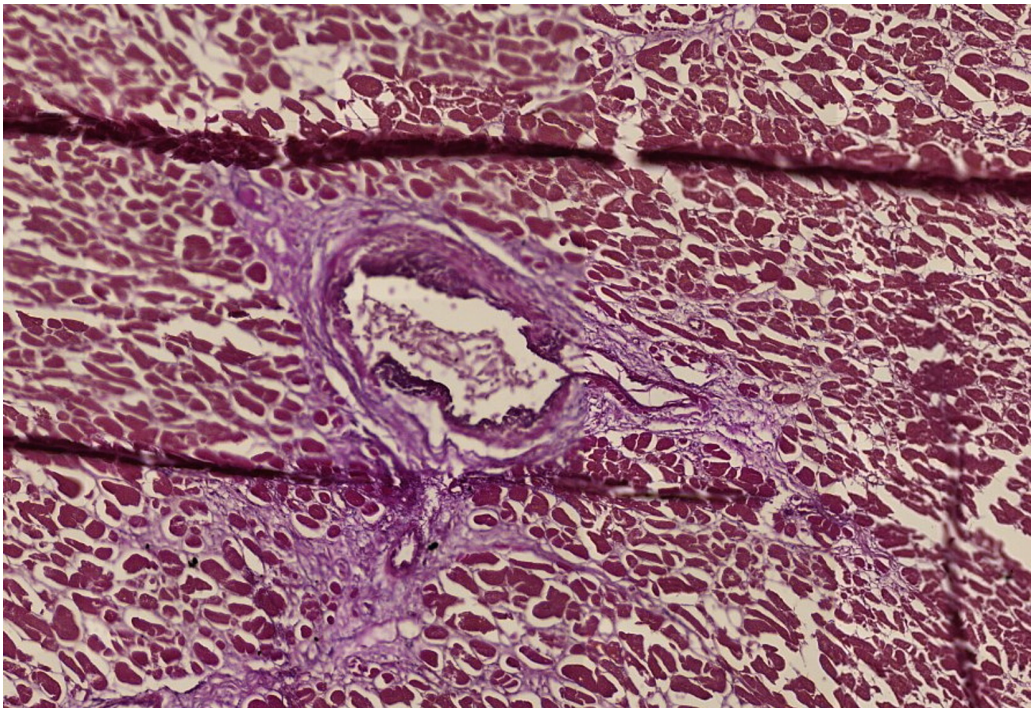

17-7-Heart-EvG-1

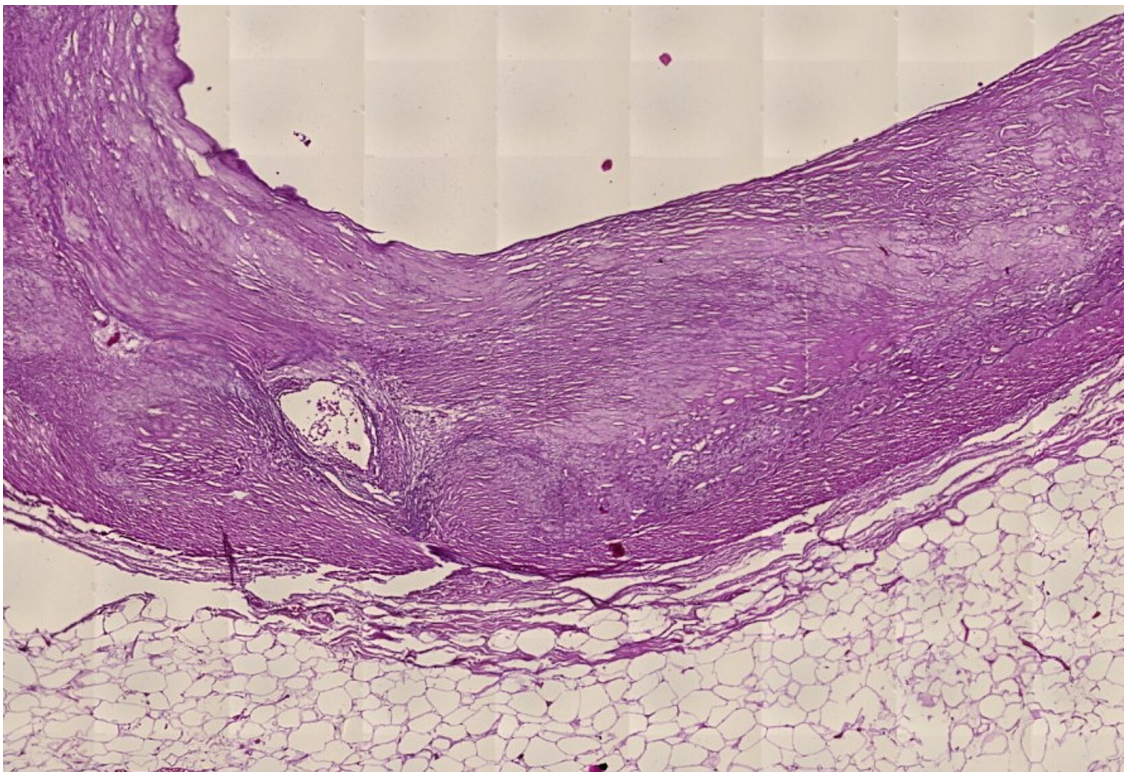

17-7-Heart-EvG-2-a 993

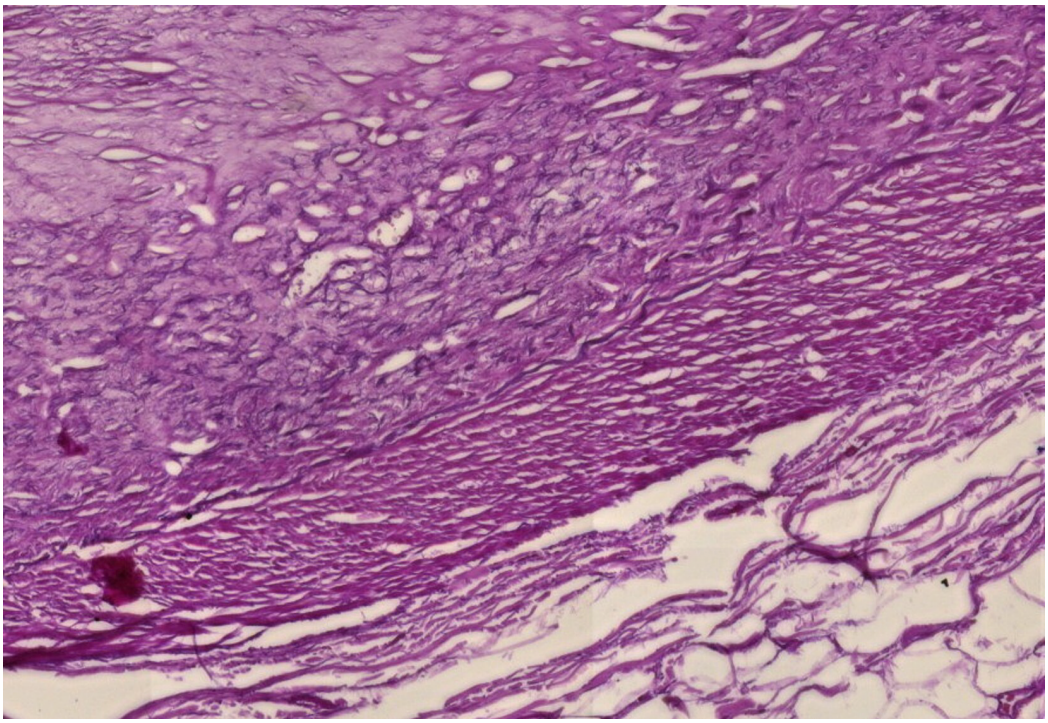

17-7-Heart-EvG-2-b

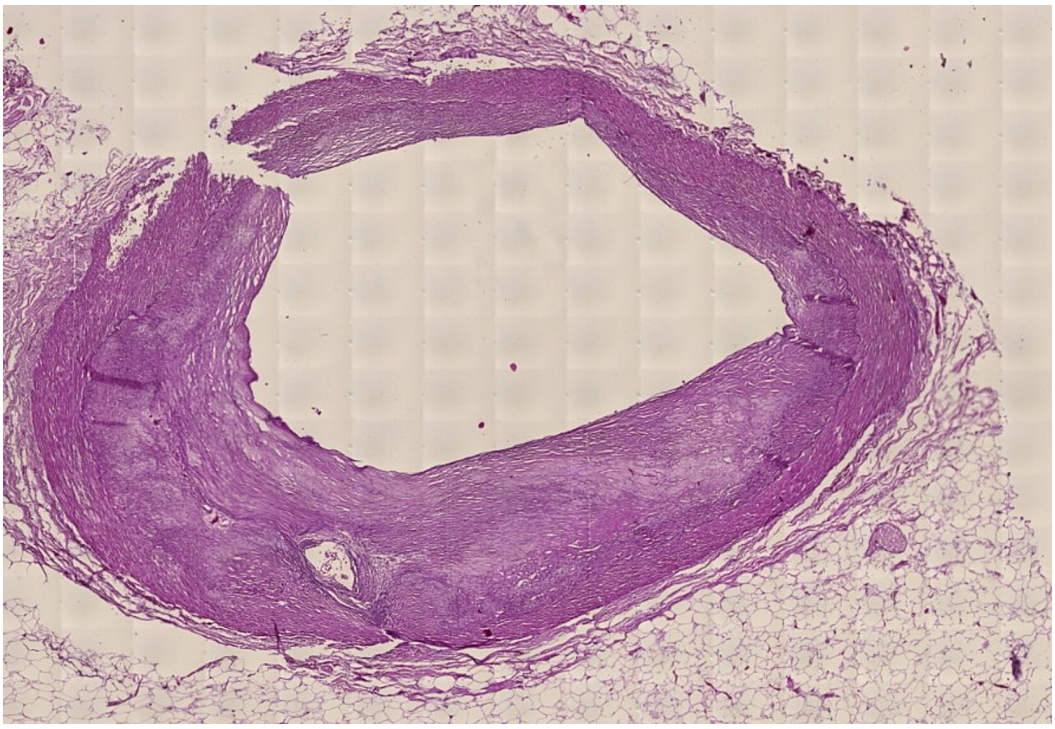

17-7-Heart-EvG-2

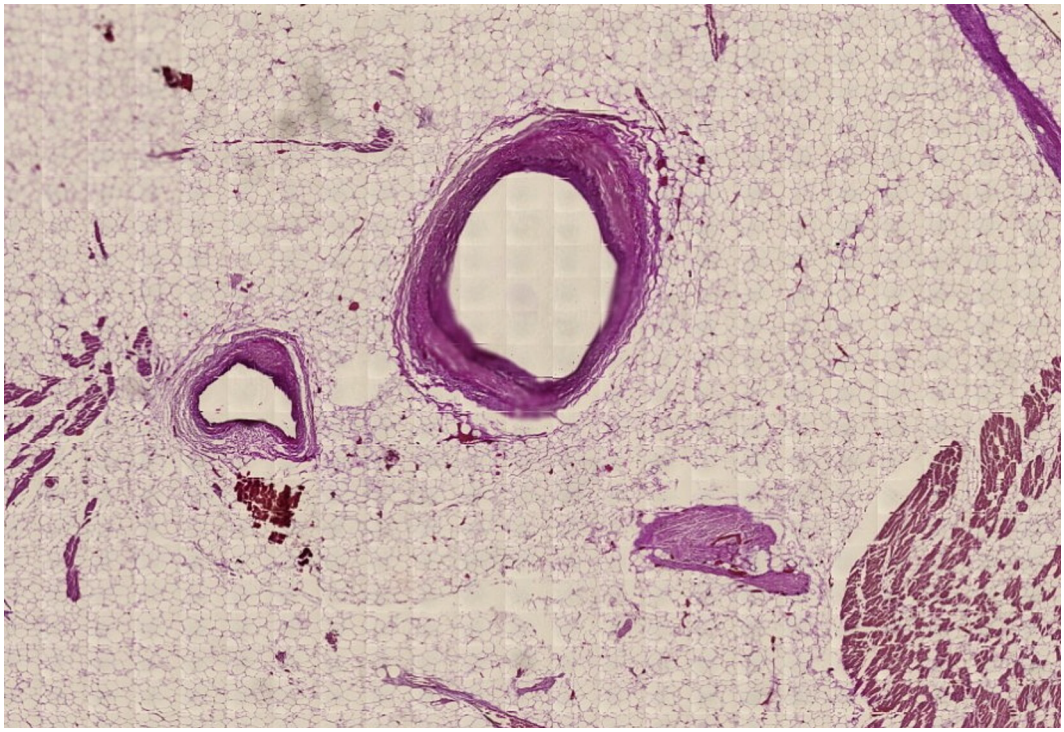

17-7-Heart-EvG-3

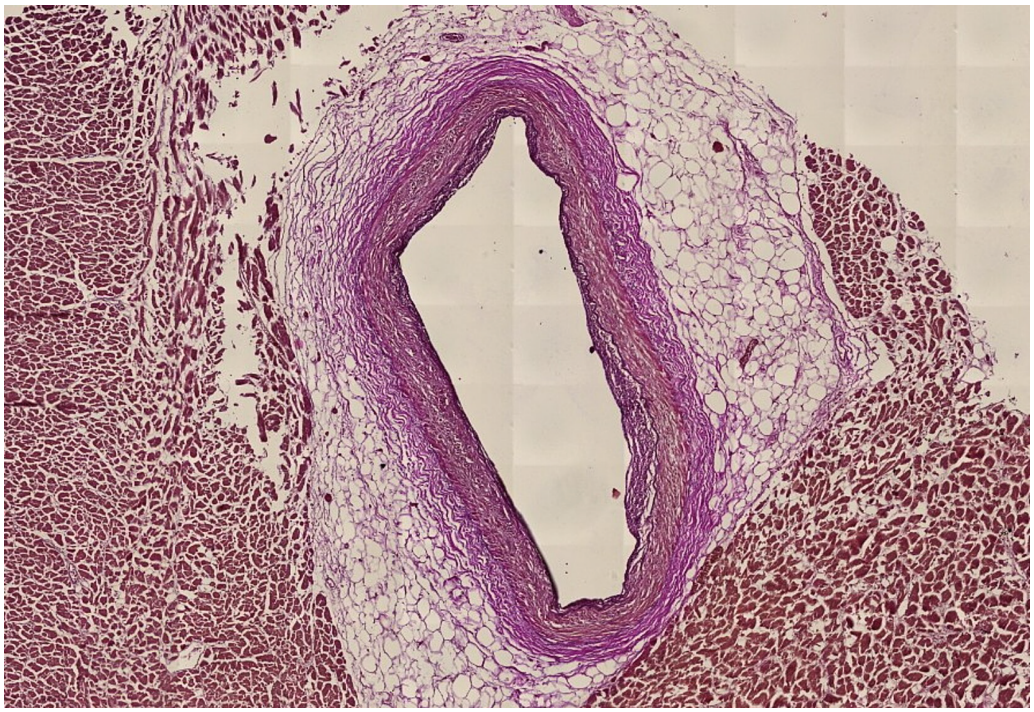

17-7-Heart-EvG-a 997

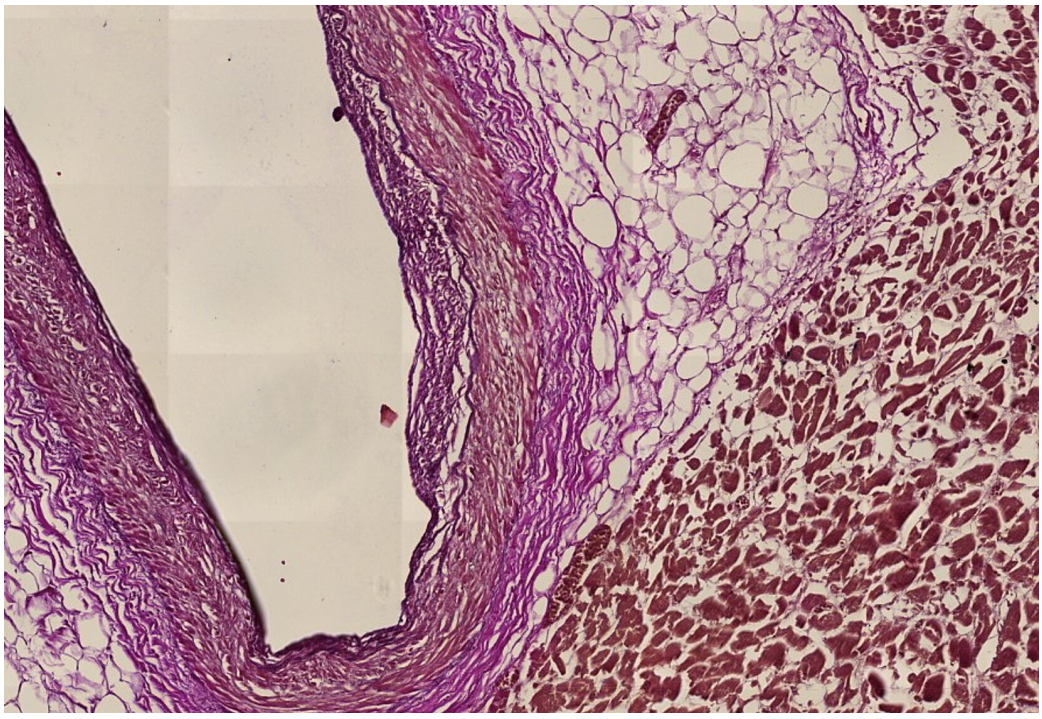

17-7-Heart-EvG-b 998

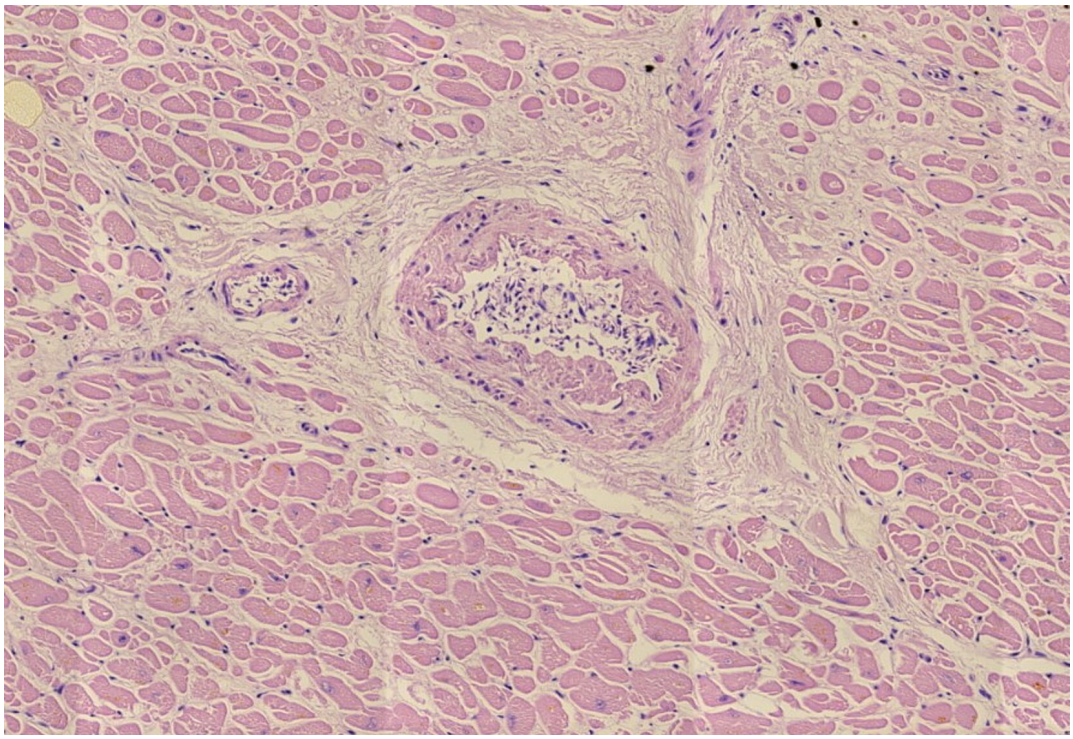

17-7-Heart 1000

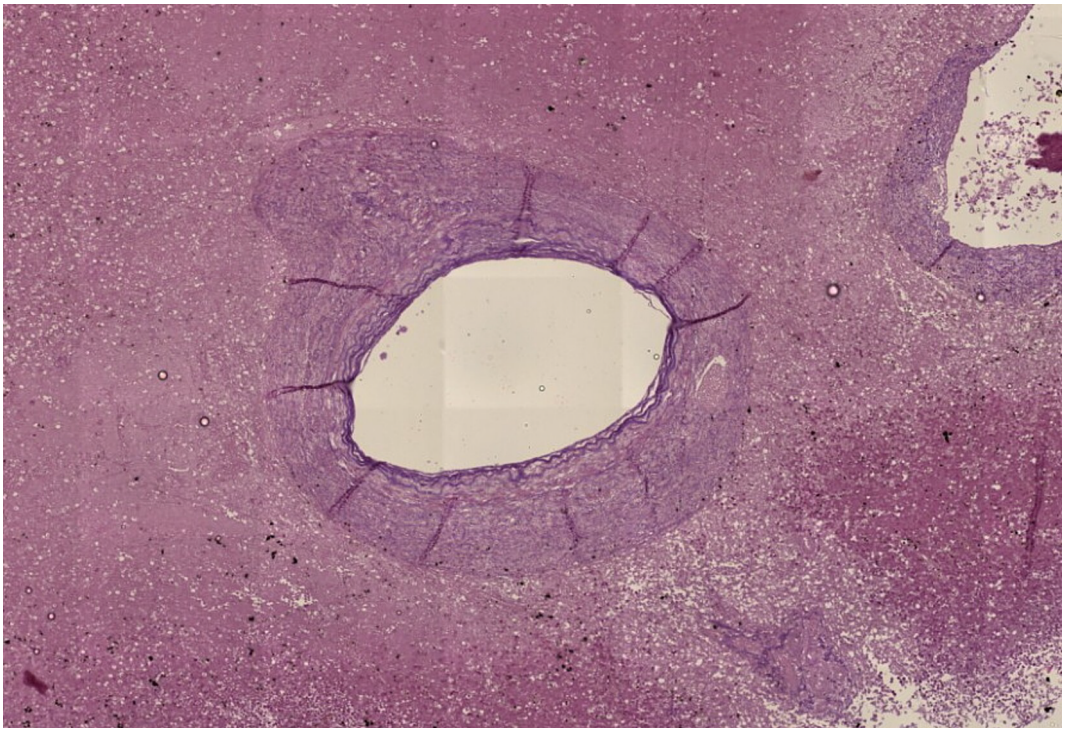

17-7-Spleen-EvG-a 1001

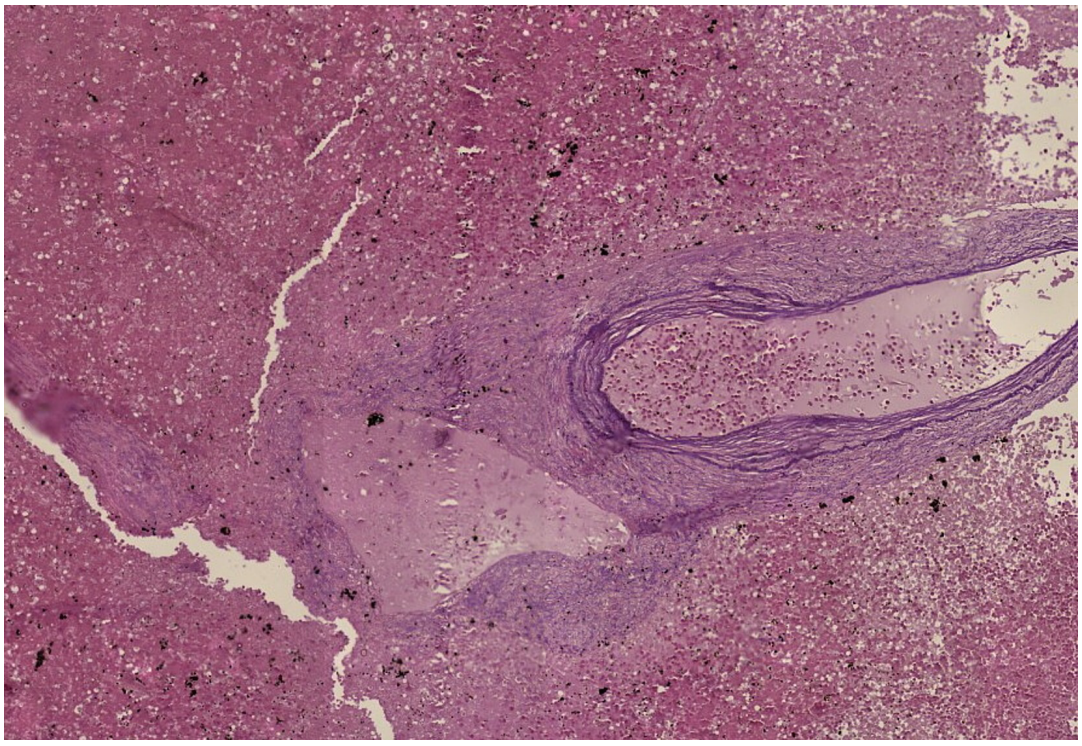

17-7-Spleen-EvG

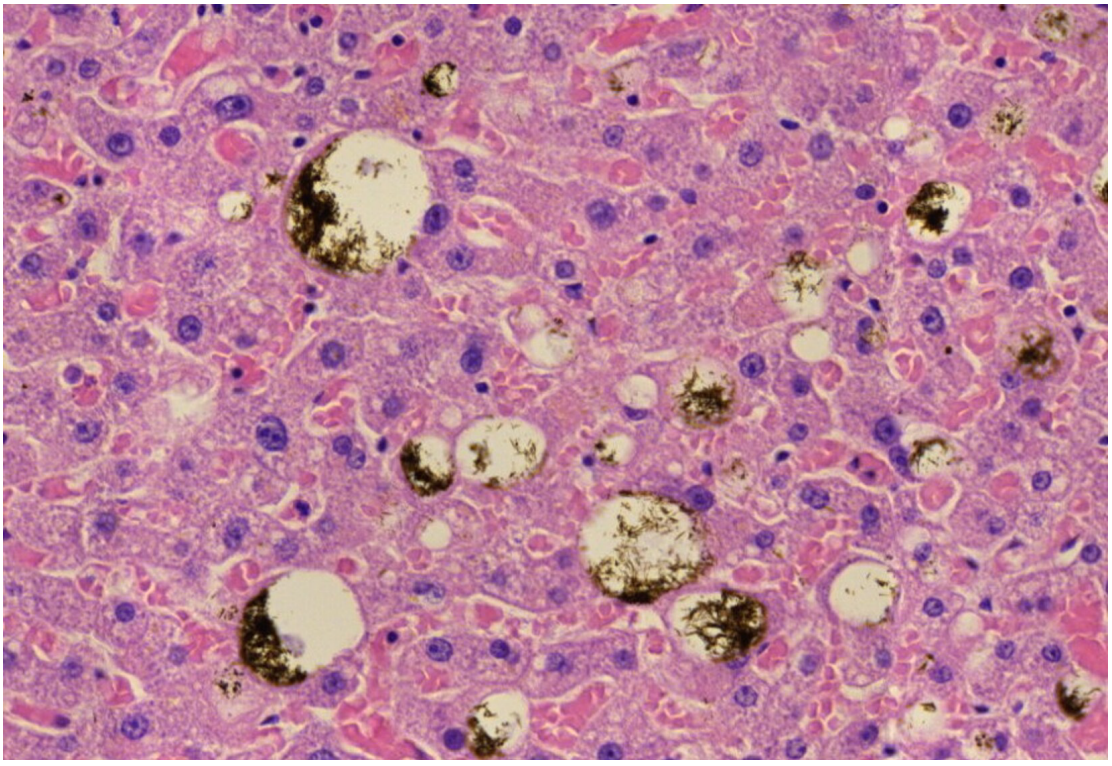

17-8-Liver-a 1003

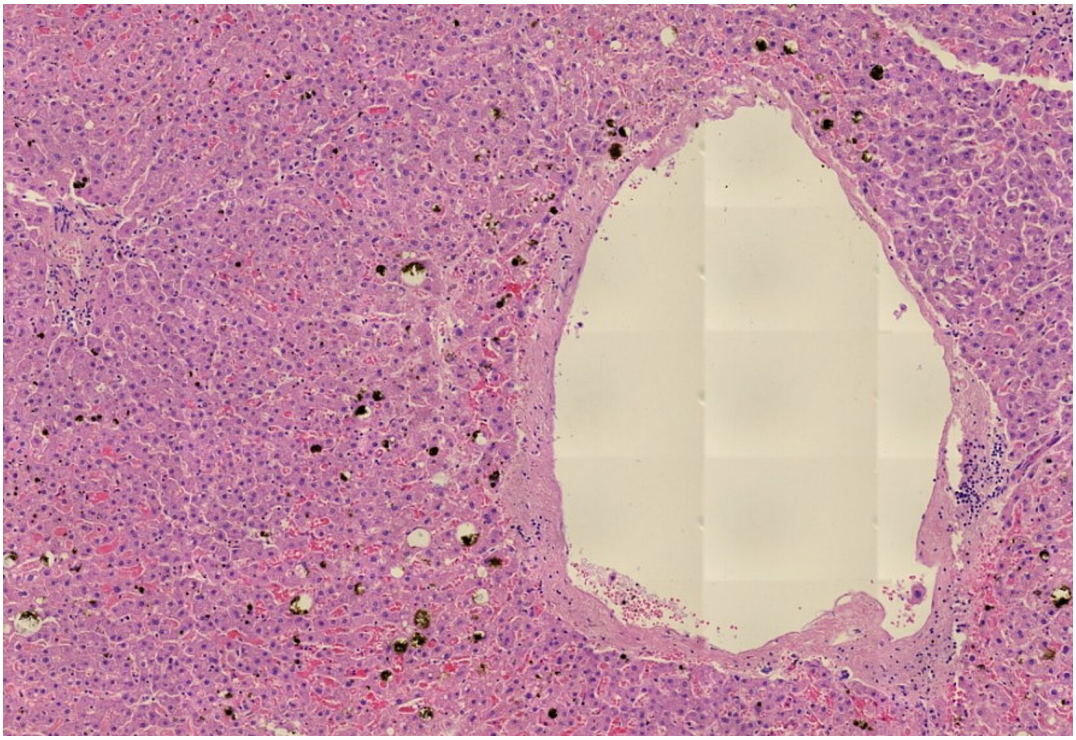

17-8-Liver-c 1004

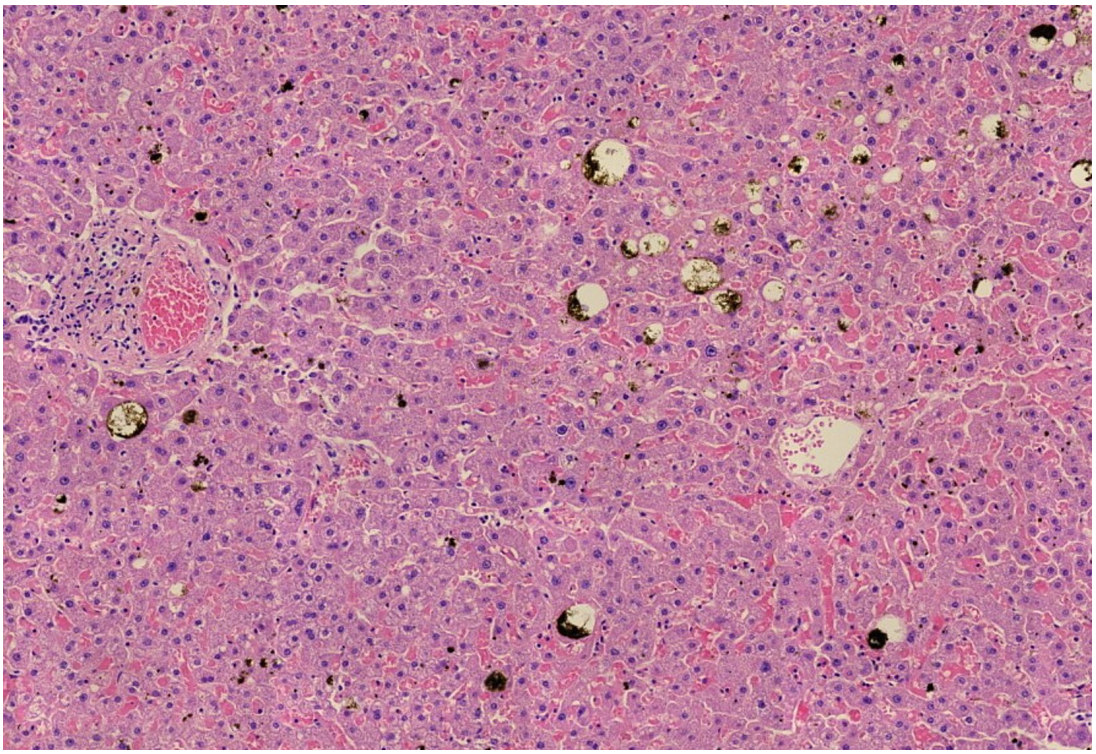

17-8-Liver 1005

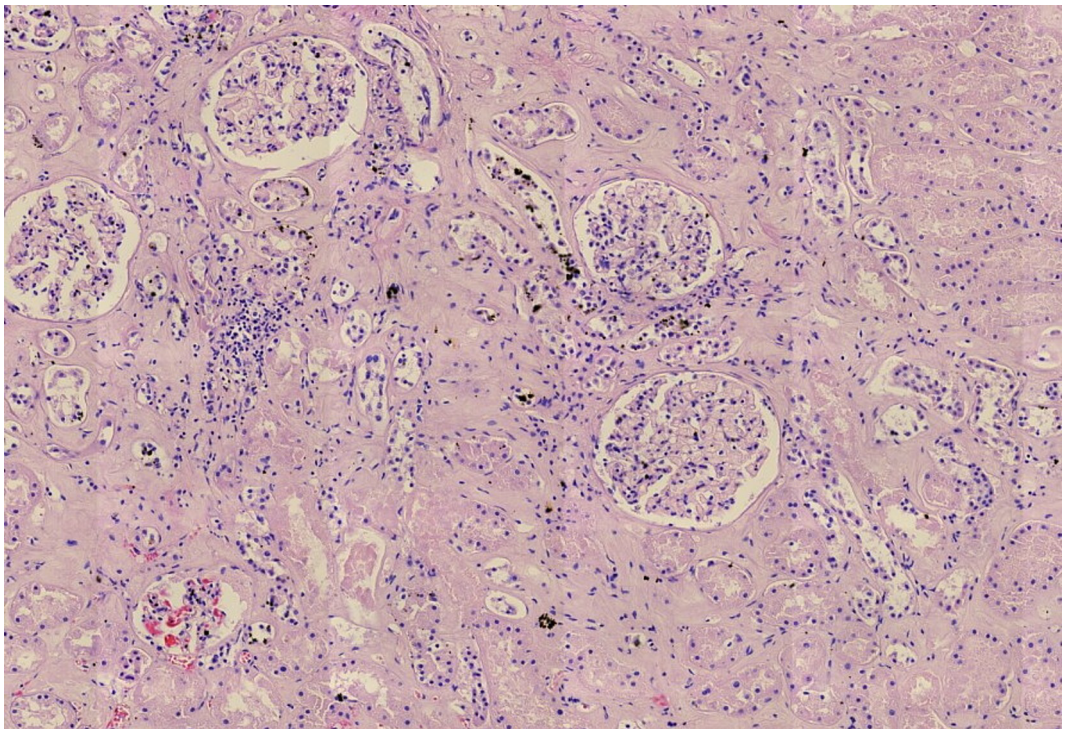

17-9-Kidney 1006

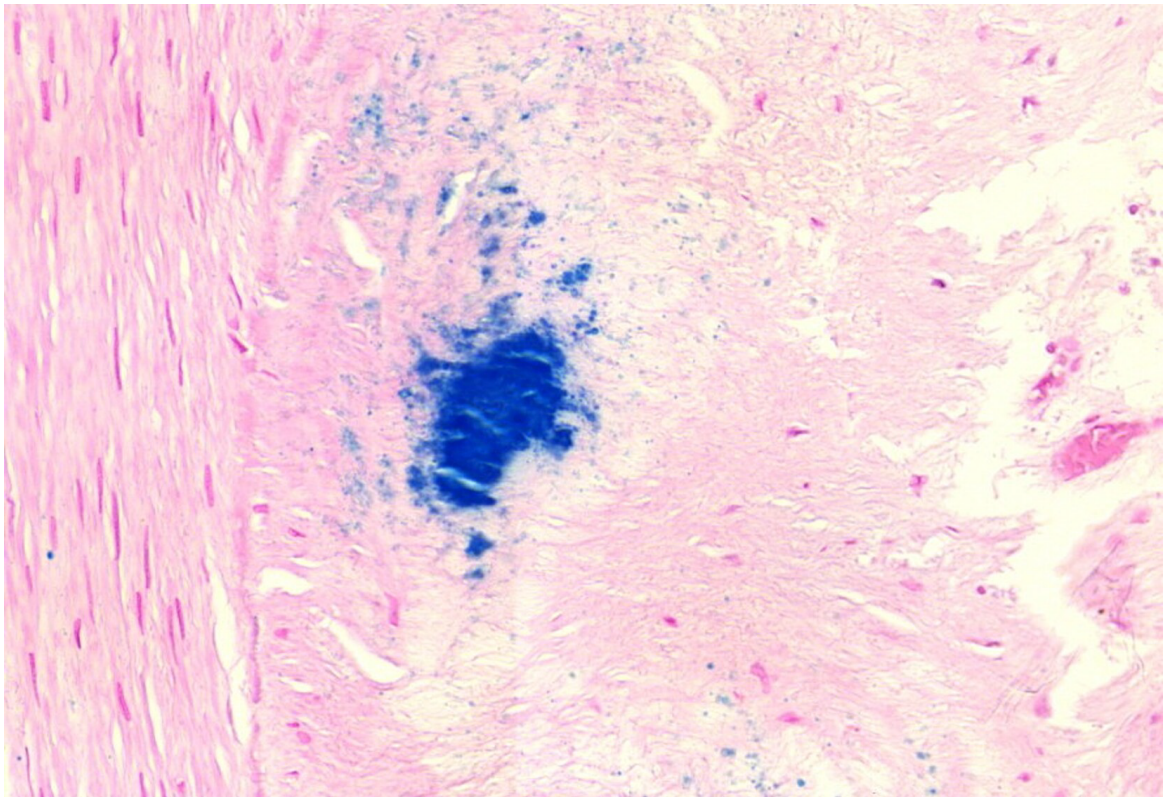

17-Coronary artery FE-aa 1007

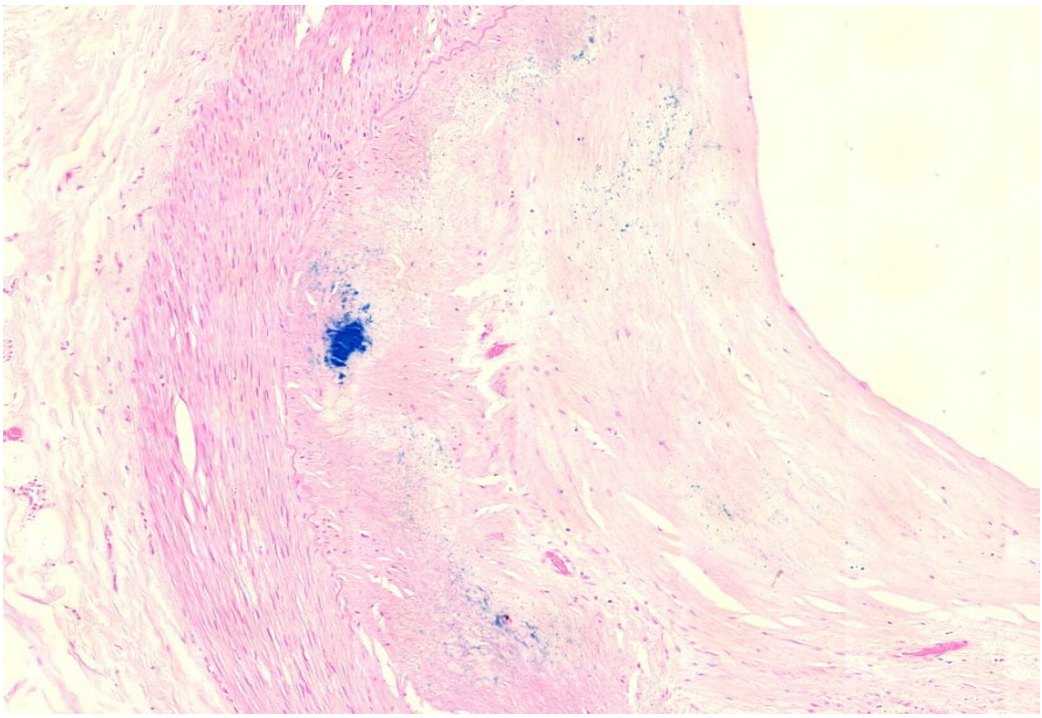

17-Coronary artery FE 1008

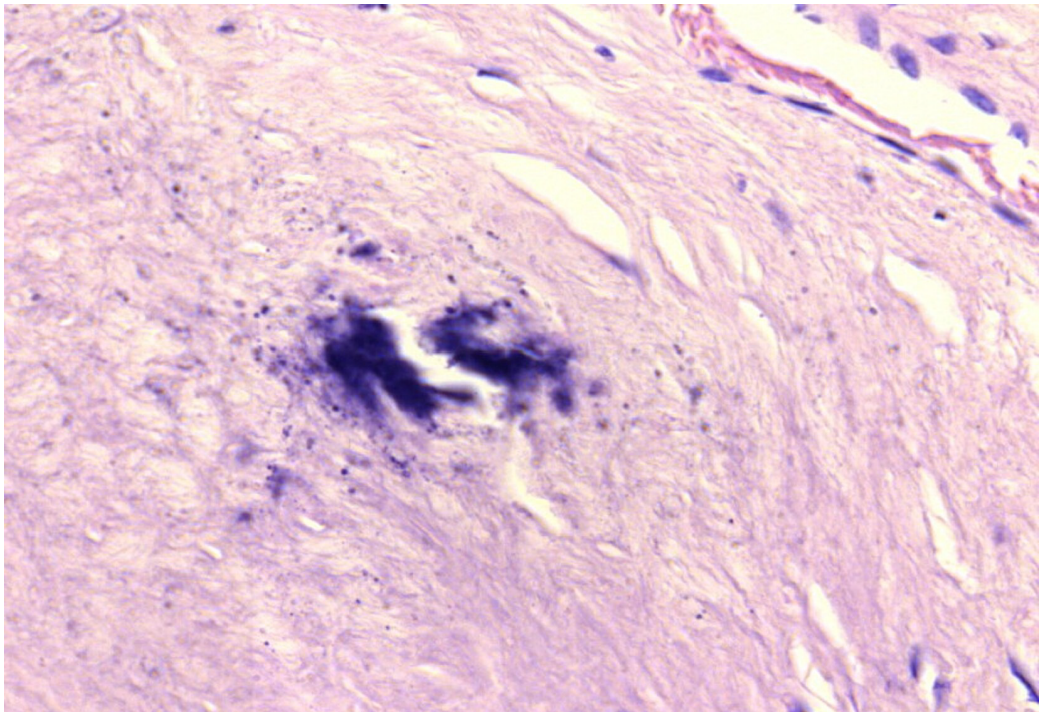

17-Coronary artery a 1009

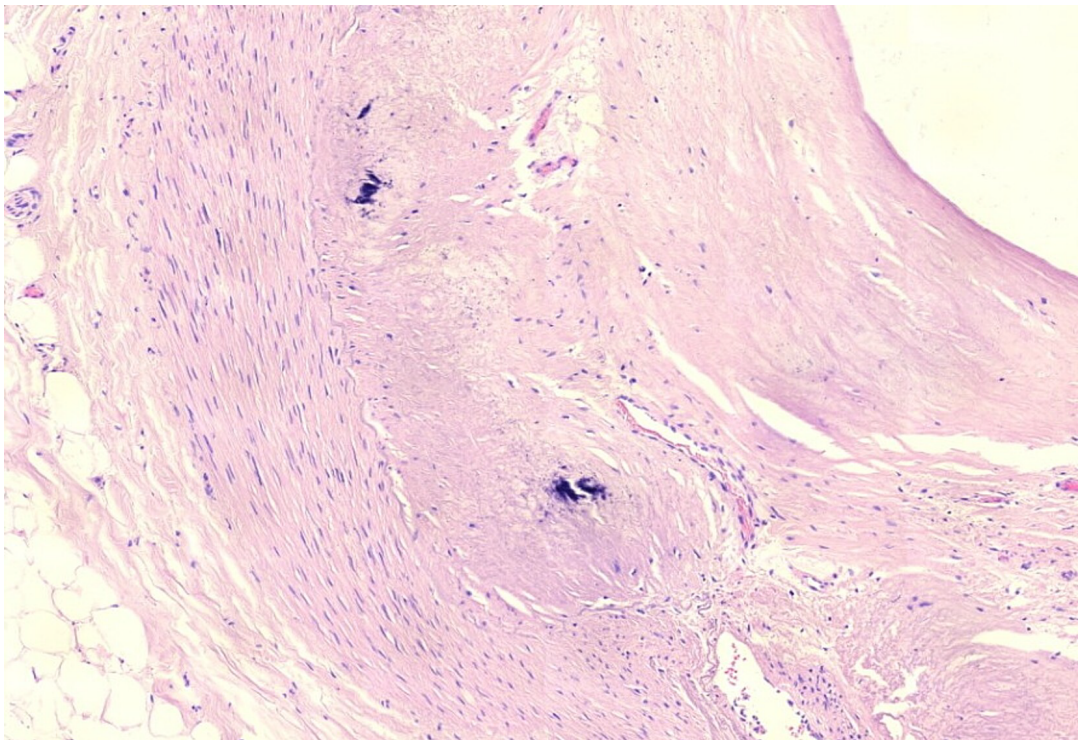

17-Coronary-Artery

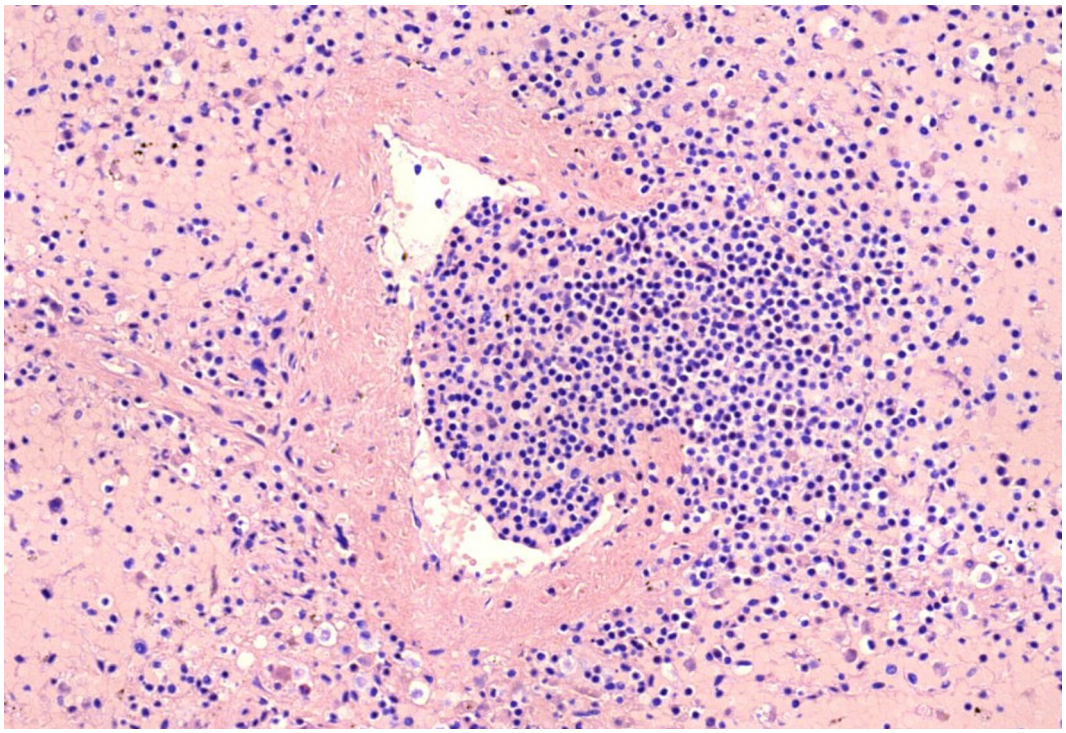

17-Spleen-3-a

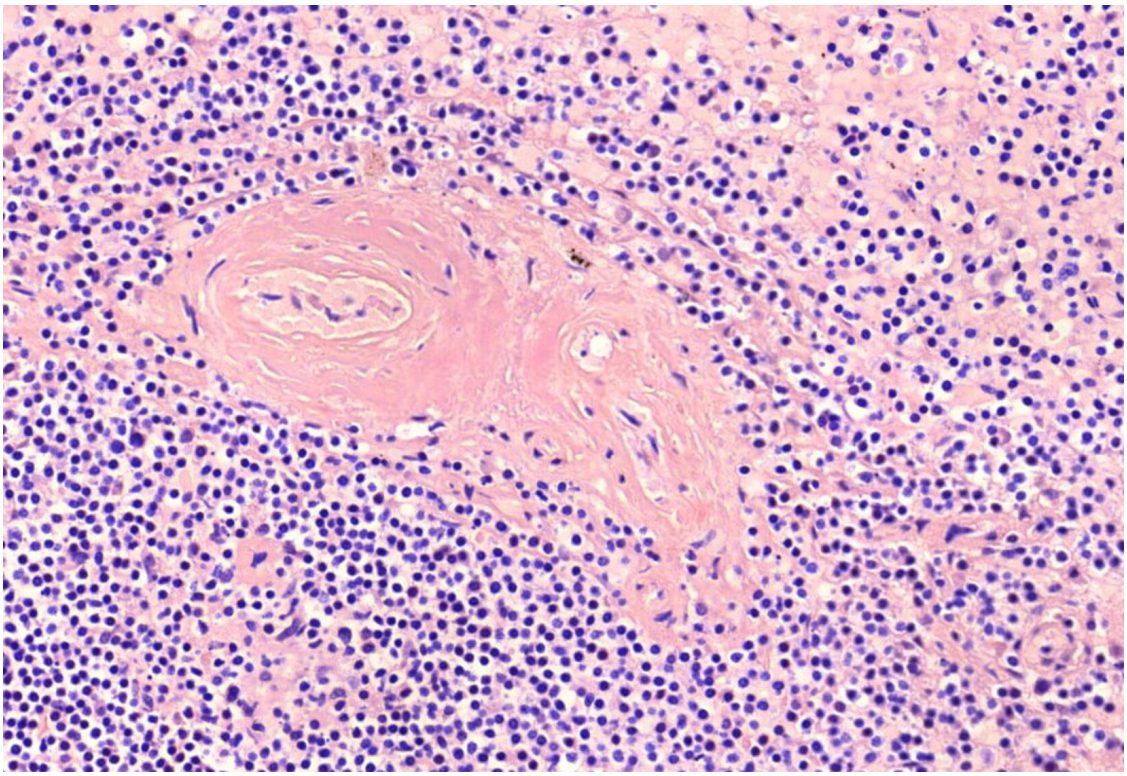

17-Spleen-3-b

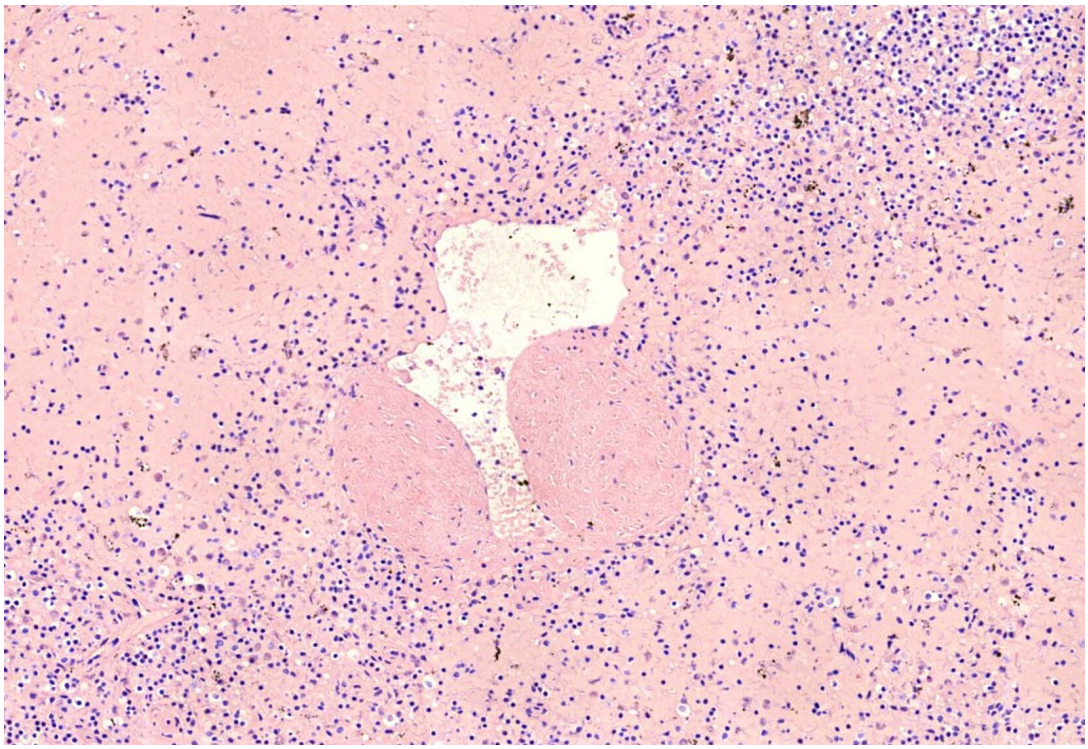

17-Spleen-3-c

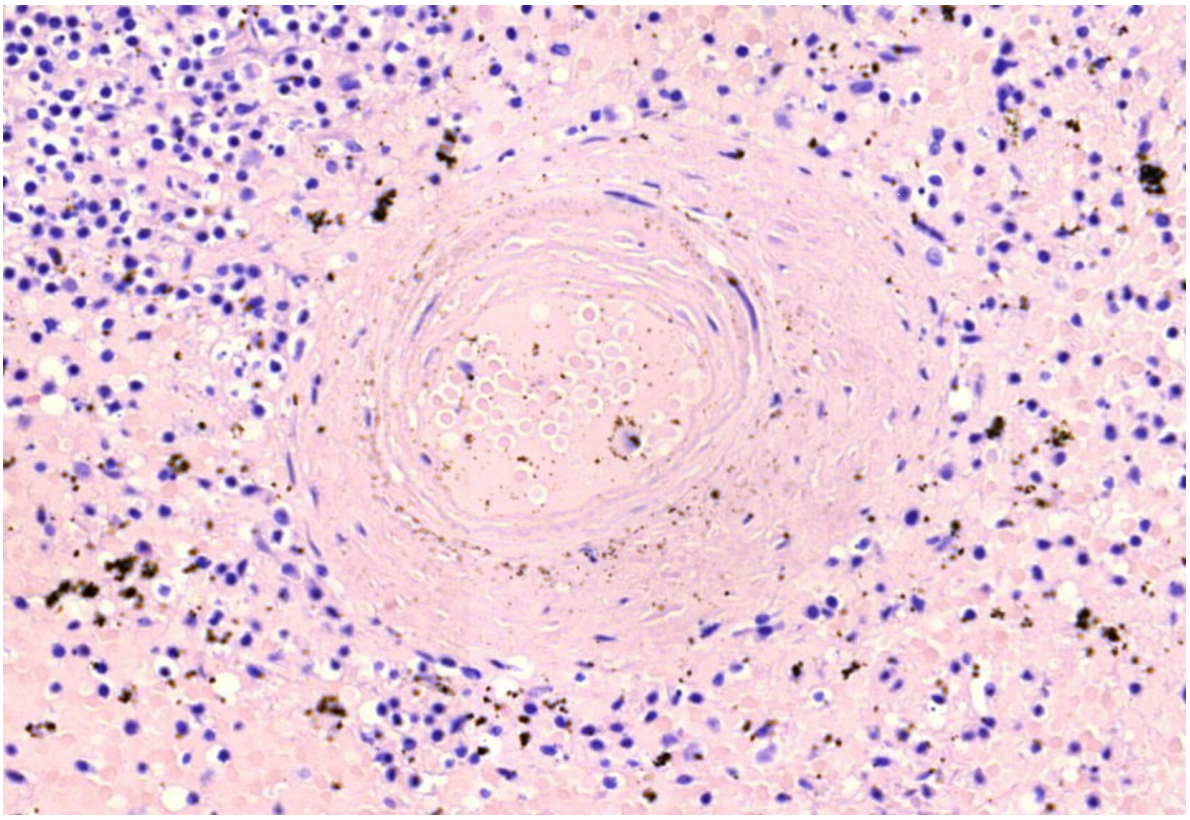

17-Spleen-3-d

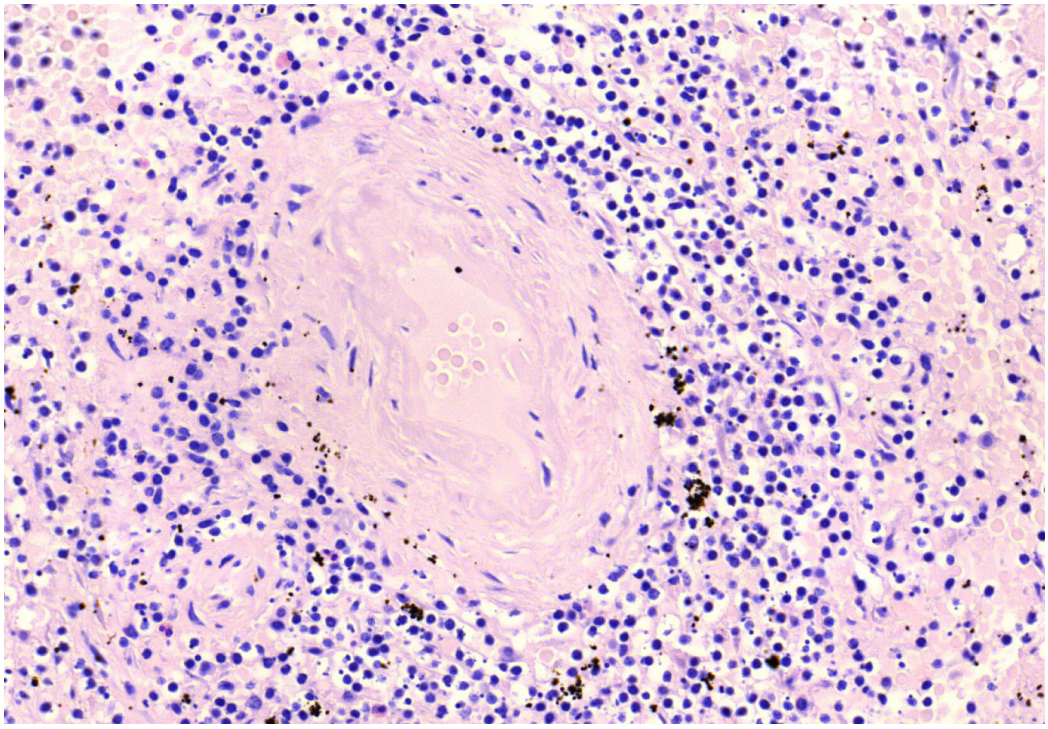

17-Spleen-3-e

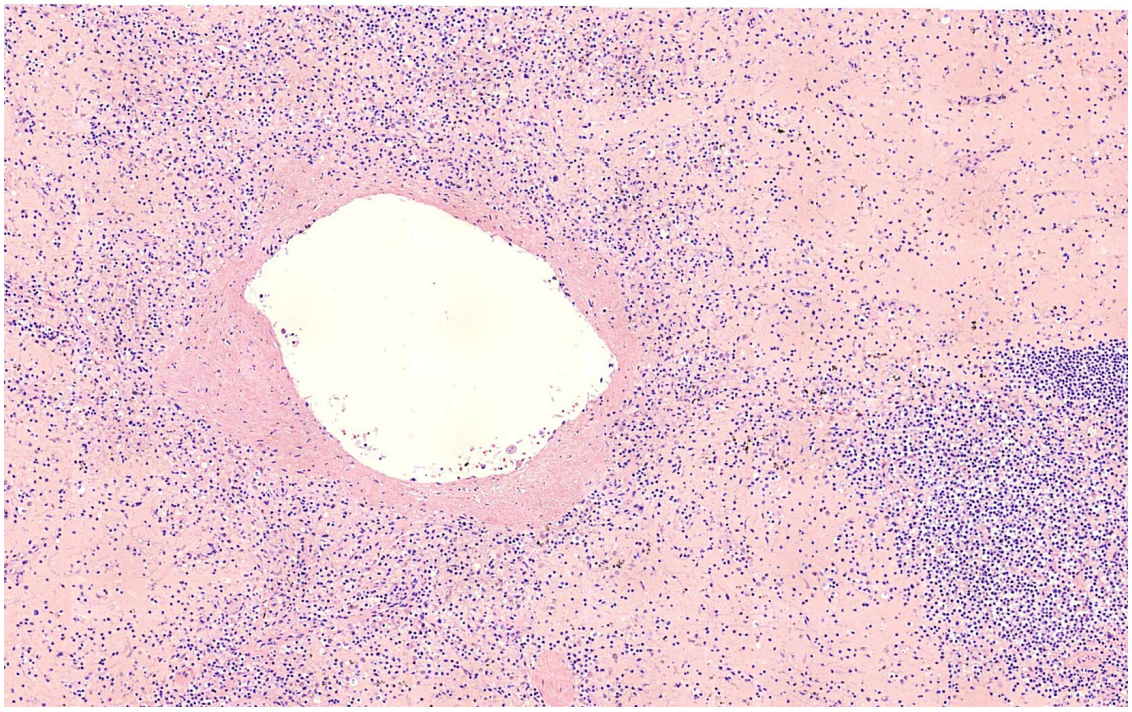

17-Spleen-3-f

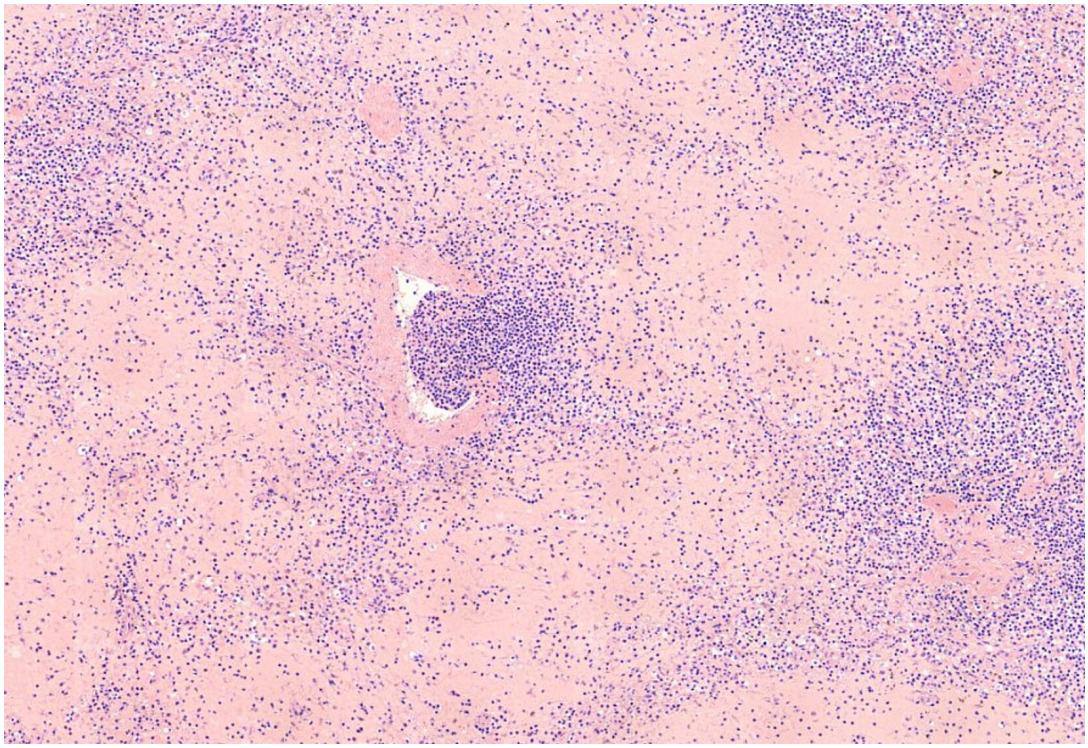

17-Spleen-3

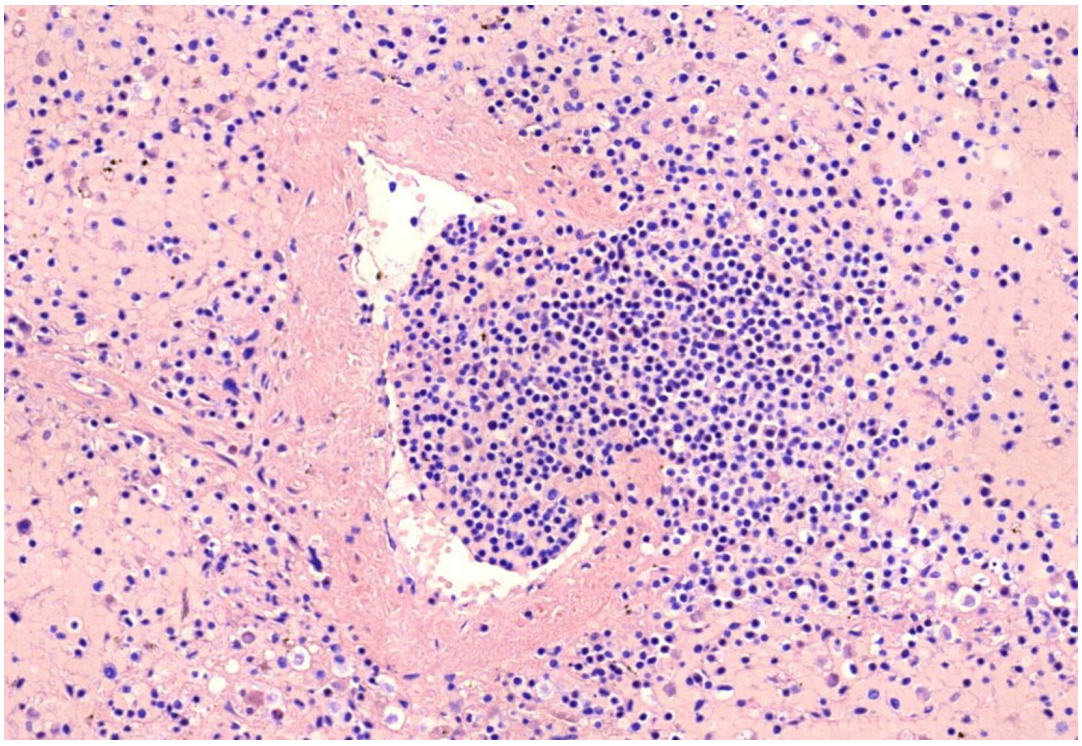

17-Spleen-3a

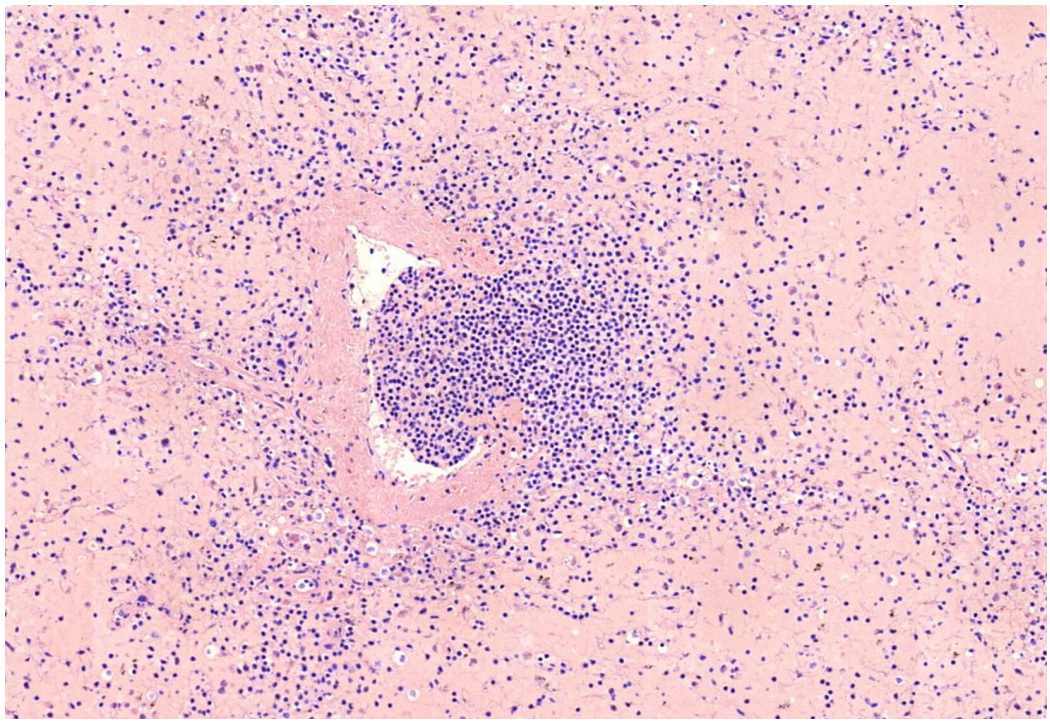

17-Spleen-3aa

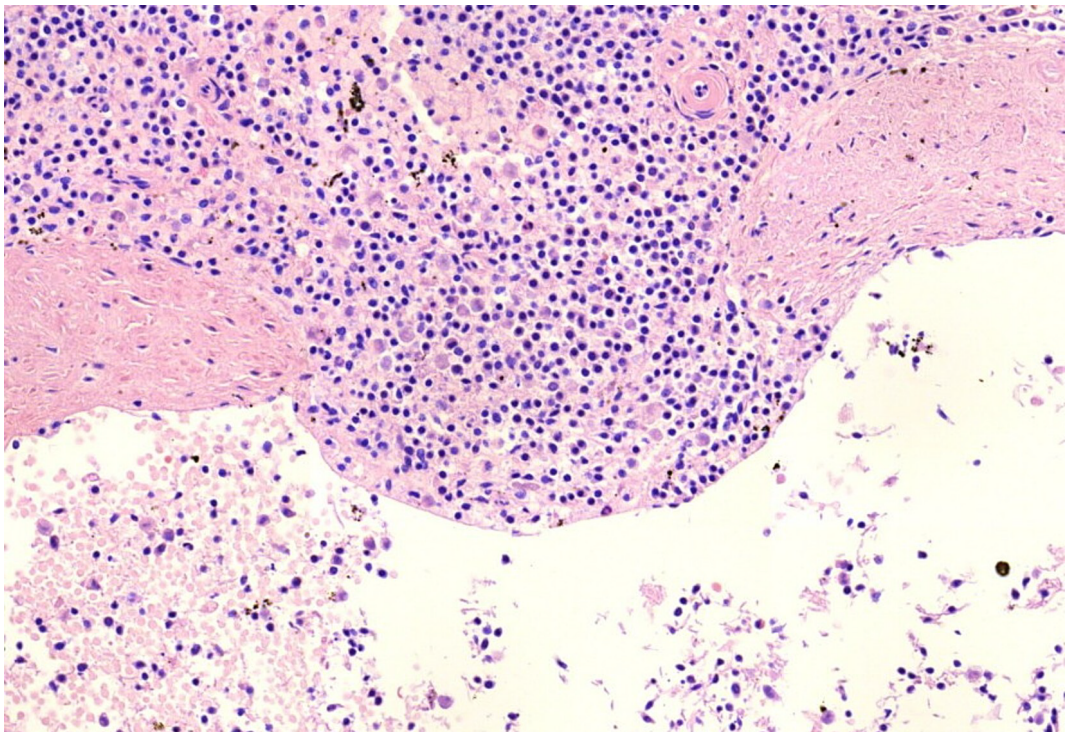

17-Spleen-a

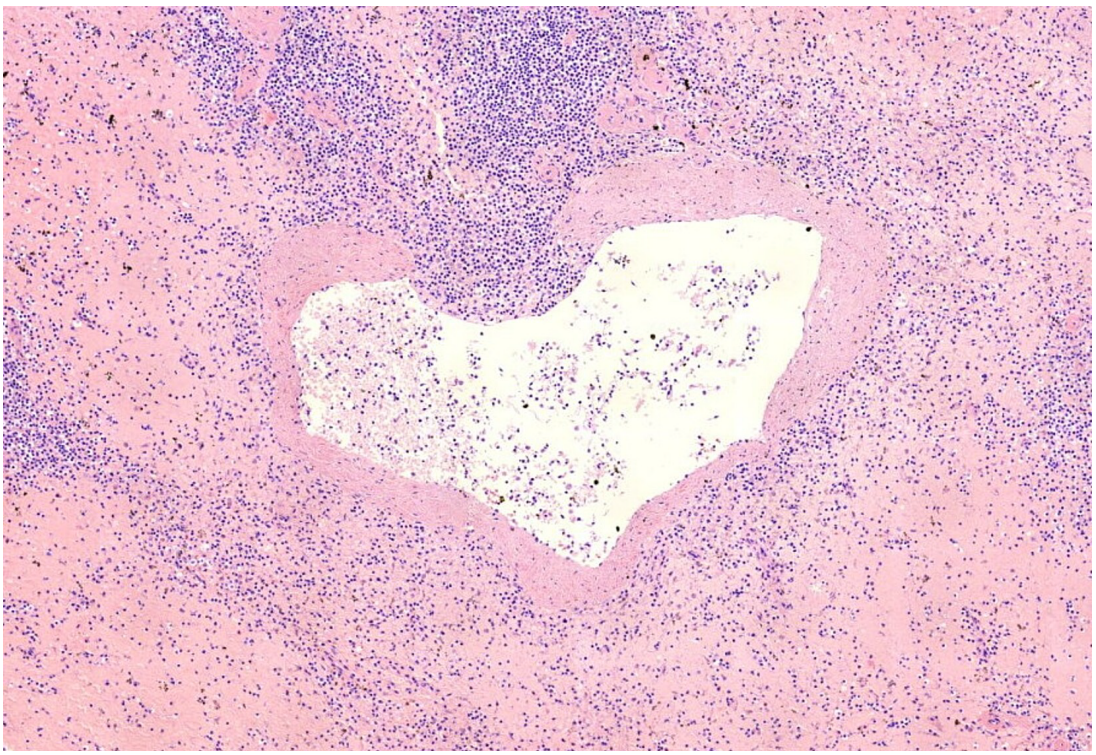

17-Spleen

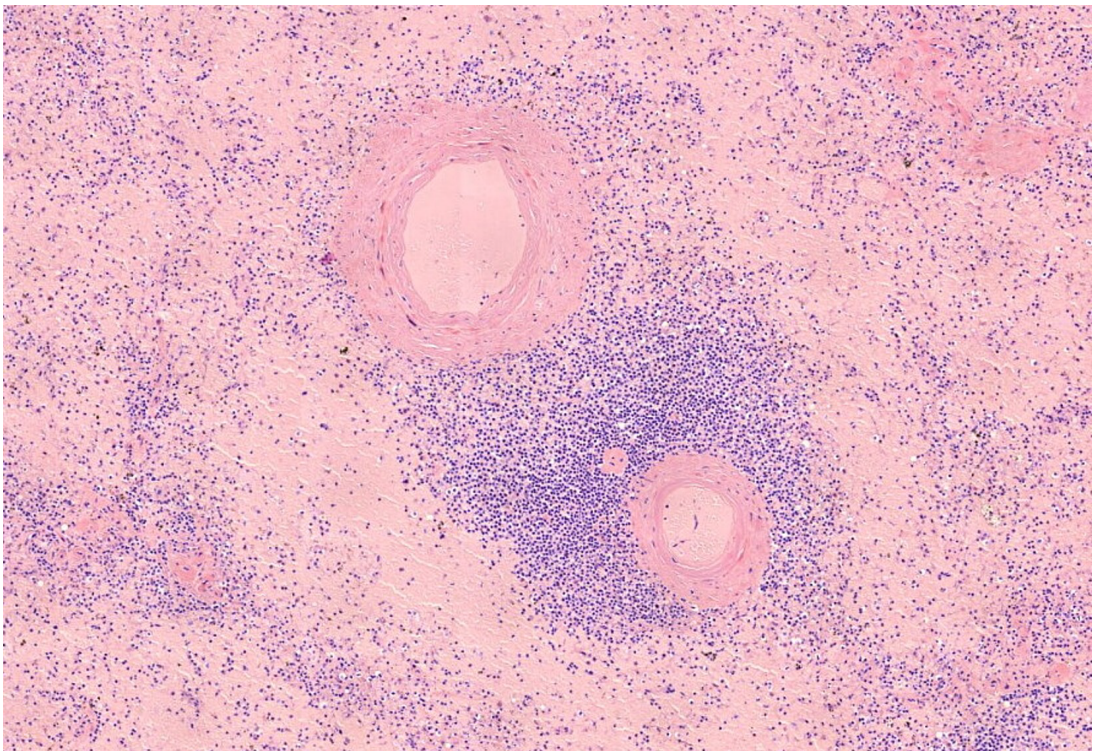

17-Spleena

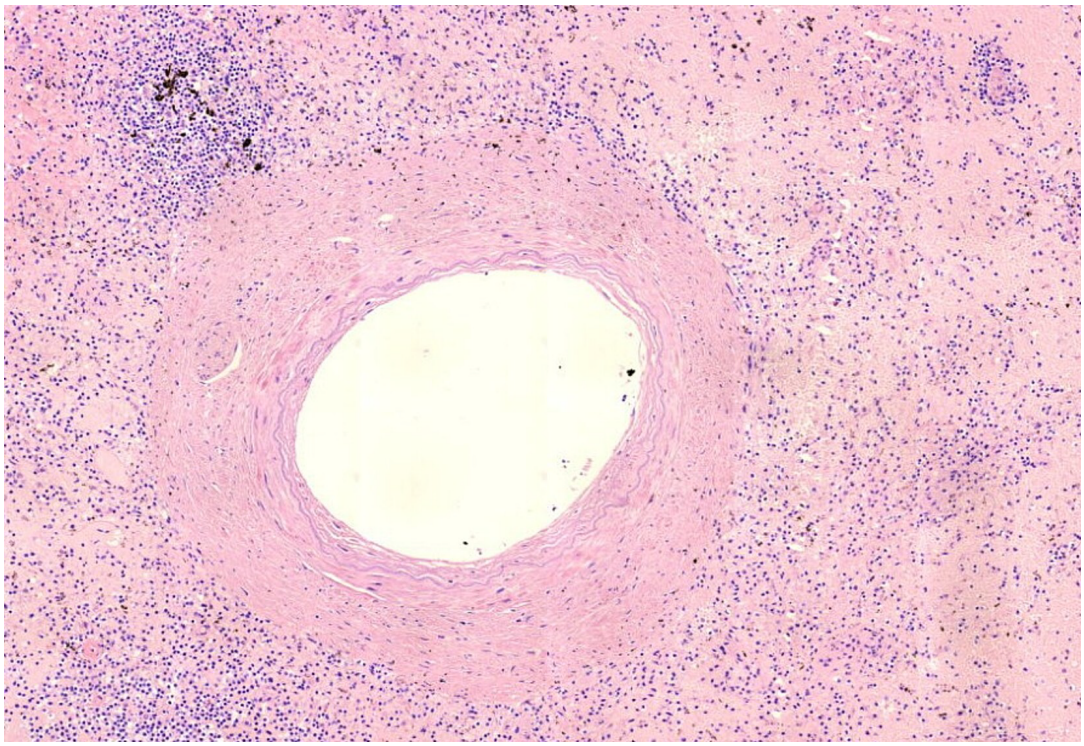

17-Spleen-2