

COUNTY OF LOS ANGELES  
DEPARTMENT OF  
MEDICAL EXAMINER-CORONER

19

STATE OF CALIFORNIA  
COUNTY OF LOS ANGELES  
IN THE MATTER OF THE DEATH OF

CC#2022-10791

Brignole, Douglas Paul

The Medical Examiner- Coroner of the County of Los Angeles Certifies:

That on the 14th day of October, 2022, in accordance with the law, he inquired into the circumstances surrounding the death of the above-mentioned person, caused an examination and identification to be made of the body and found that the deceased was named:

Douglas Paul Brignole

a MALE , age about 62 years; that HE  came to HIS  death on the 13th day of October, 2022 at:

Residence

1421 South Sherbourne Drive

Los Angeles, California 90035

Los Angeles County, California; and that was caused by:

Covid -19 Infection

Mode: Natural

Given under my hand this 7th day of November, 2022

By: Guadalupe Bocanegra  
Deputy Coroner, Please Print

  
Signature, Please Sign

**This is a true certified copy of the record  
if it bears the seal of the Department of  
Medical Examiner - Coroner  
imprinted in purple ink.**



**CHIEF MEDICAL EXAMINER - CORONER  
DEPARTMENT OF MEDICAL EXAMINER - CORONER  
LOS ANGELES COUNTY, CALIFORNIA**



51

EXAMINATION PROTOCOL

2022-10791  
BRIGNOLE, DOUGLAS PAUL

Page 1 of 2

The body is identified by medical examiner toe tags and ankle band.

The body

is clothed  
 was not clothed

and I

inspected the clothing.  
 did not see the clothing.

Rigor and livor are altered.

Appears:  Asian  Black  Caucasian  Hispanic  Indian

Sex:  Male  Female. Appears the stated age of: 62 years

The body weighs approximately 185 pounds, measures approximately 68 inches and is

well-nourished and appropriately developed for age.

Embalmed:  No  Yes

Irides:  Blue  Brown  Green

Sclera:  Normal  Icteric  Congested without petechial hemorrhages

Conjunctival Petechial Hemorrhage:  No  Yes

Head Hair:  Gray and short in length

Facial hair:  Absent  Present, stubble

Teeth:  Absent  Present

Dentures:  Absent  Present

Scars:  None identified  Present

Tattoos:  None identified  Present

EVIDENCE OF THERAPEUTIC INTERVENTION:  
There is no evidence of recent therapeutic intervention.

The chest has no increased anterior-posterior diameter. The extremities are well-developed and symmetrical.

The abdomen is

flat.

The genitalia are those of an adult

female.  
 male

**EXAMINATION PROTOCOL**

**2022-10791**

page 2 of 2

**EVIDENCE OF INJURY:**

A small tan-brown abrasion involves the left forehead. Scattered abrasions involve the feet.

- |                  |   |  |             |                              |  |
|------------------|---|--|-------------|------------------------------|--|
| Exam photographs | <input type="checkbox"/> Yes            | <input checked="" type="checkbox"/> No | Fluoroscopy | <input type="checkbox"/> Yes | <input checked="" type="checkbox"/> No |
| X-Rays           | <input type="checkbox"/> Yes            | <input checked="" type="checkbox"/> No | Cultures    | <input type="checkbox"/> Yes | <input checked="" type="checkbox"/> No |
| Toxicology       | <input checked="" type="checkbox"/> Yes | <input type="checkbox"/> No            | Cassettes   | <input type="checkbox"/> Yes | <input checked="" type="checkbox"/> No |
| GSR              | <input type="checkbox"/> Yes            | <input checked="" type="checkbox"/> No | Evidence    | <input type="checkbox"/> Yes | <input checked="" type="checkbox"/> No |

A nasopharyngeal swab for common viral pathogens is positive for SARS-CoV-2. Indicate other form number(s) attached. #20

**PATHOLOGIC DIAGNOSES**

- I. Complications of COVID-19 infection
  - A. Nasopharyngeal swab positive for SARS-CoV-2 (COVID-19)
- II. Atherosclerotic cardiovascular disease
  - A. Hyperlipidemia, reported
  - B. Unspecified cardiac disease, reported
- III. Blunt trauma, minor
  - A. Abrasion, forehead
  - B. Abrasions, feet

**SUMMARY AND OPINION**

Douglas Brignole was a 62-year-old man with reported medical history of hyperlipidemia, hypogonadism, and unspecified cardiac disease.

According to the Medical Examiner Investigator's report, Mr. Brignole was found unresponsive on the ground in his home. Emergency medical services were contacted, and he was pronounced deceased. He was reportedly feeling unwell recently.

External examination revealed a well-developed man without trauma to explain death. Small scrapes involved his forehead and feet.

Toxicology testing will not be performed. A nasopharyngeal swab for common respiratory viruses was positive for SARS-CoV-2 (COVID-19).


Mr. Brignole was positive for infection with the novel coronavirus, which is the cause of COVID-19. COVID-19 can result in a spectrum of immune responses that range from asymptomatic and mild, to severe respiratory symptoms and death in susceptible individuals. Inflammation and fluid-buildup in the lungs (in response to the infection) prevents the lungs from being able to adequately exchange oxygen with the environment. When severe, organ damage and organ failure from lack of oxygen can occur, which can cause death. Mr. Brignole's underlying medical conditions, including heart disease from atherosclerosis would have made him less able to tolerate the effects of COVID-19, contributing to death.

Given the available investigative information and exam, it is my opinion that the cause and manner of death are best certified as:


CAUSE OF DEATH: COVID-19 INFECTION

CONTRIBUTING FACTOR: ATHEROSCLEROTIC CARDIOVASCULAR DISEASE

MANNER OF DEATH: NATURAL



Michael Harrell, M.D.  
Deputy Medical Examiner



Date

15

AUTOPSY CLASS:  A  B  C  Examination Only D  
 FAMILY OBJECTION TO AUTOPSY  
Date 10/14 Time 9:50 Dr. Michael Horvath  
FINAL ON: 10/21/2022 By: Michael Horvath  
(Print) (Print)

APPROXIMATE INTERVAL BETWEEN DEATHS AND DEATH

2022-10791  
BRIGNOLE, DOUGLAS  
MAY 314

DEATH WAS CAUSED BY (Enter only one cause per line for A, B, C, and D)

IMMEDIATE CAUSE:  
(A) Covid-19 infection

Age 62 Gender:  Male  Female

DUE TO, OR AS A CONSEQUENCE OF  
(B)

PRIOR EXAMINATION REVIEW BY DME  
 BODY TAG  CLOTHING  
 X-RAY (No \_\_\_\_\_)  FLUORO  
 SPECIAL PROCESSING TAG  MED. RECORDS  
 AT SCENE PHOTOS (No \_\_\_\_\_)

DUE TO, OR AS A CONSEQUENCE OF  
(C)

CASE CIRCUMSTANCES  
 EMBALMED  
 DECOMPOSED  
 >24 HRS IN HOSPITAL  
 OTHER: \_\_\_\_\_ (Reason)

DUE TO, OR AS A CONSEQUENCE OF  
(D)

OTHER CONDITIONS CONTRIBUTING BUT NOT RELATED TO THE IMMEDIATE CAUSE OF DEATH  
Atherosclerotic cardiovascular disease

TYPING SPECIMEN  
TYPING SPECIMEN TAKEN BY Horvath  
SOURCE Trunk

NATURAL  SUICIDE  HOMICIDE  
 ACCIDENT  COULD NOT BE DETERMINED

TOXICOLOGY SPECIMEN  
COLLECTED BY Horvath  
 HEART BLOOD  STOMACH CONTENTS  
 FEMORAL BLOOD  VITREOUS

If other than natural causes, HOW DID INJURY OCCUR?

TECHNIQUE East  
 Right BLOOD  SPLEEN  
 Left BLOOD  KIDNEY  
 BILE   
 LIVER   
 URINE   
URINE GLUCOSE DIPSTICK RESULT: 4+ 3+ 2+ 1+ 0  
TOX SPECIMEN RECONCILIATION BY: ecfs

WAS OPERATION PERFORMED FOR ANY CONDITION STATED ABOVE:  YES  NO  
TYPE OF SURGERY: \_\_\_\_\_ DATE: \_\_\_\_\_

ORGAN PROCUREMENT  TECHNICIAN Flores  
PREGNANCY IN LAST YEAR:  YES  NO  UNK  NOT APPLICABLE  
 WITNESS TO AUTOPSY  EVIDENCE RECOVERED AT AUTOPSY  
Item Description:

HISTOLOGY  
 Regular (No \_\_\_\_\_)  Oversize (No \_\_\_\_\_)  
Histopath Cut:  Autopsy  Lab

62 yom, recent illness,  
⊖ illicit@ home  
held tox, pending  
NP-swabs

TOXICOLOGY REQUESTS  
FORM 3A:  YES  NO  
 NO TOXICOLOGY REQUESTED  
SCREEN  C  H  T  S  D  
 ALCOHOL ONLY  
 CARBON MONOXIDE  
 OTHER (Specify drug and tissue)

RESIDENT \_\_\_\_\_ DME \_\_\_\_\_

REQUESTED MATERIAL ON PENDING CASES  
 POLICE REPORT  MED HISTORY  
 TOX FOR COD  HISTOLOGY  
 TOX FOR R/O  INVESTIGATIONS  
 MICROBIOLOGY stool  EYE PATH. CONS  
 RADIOLOGY CONS  
 CONSULT ON \_\_\_\_\_  
 BRAIN SUBMITTED  
 NEURO CONSULT  DME TO CJT  
 CRIMINALISTICS  
 GSR  SEXUAL ASSAULT  OTHER

20

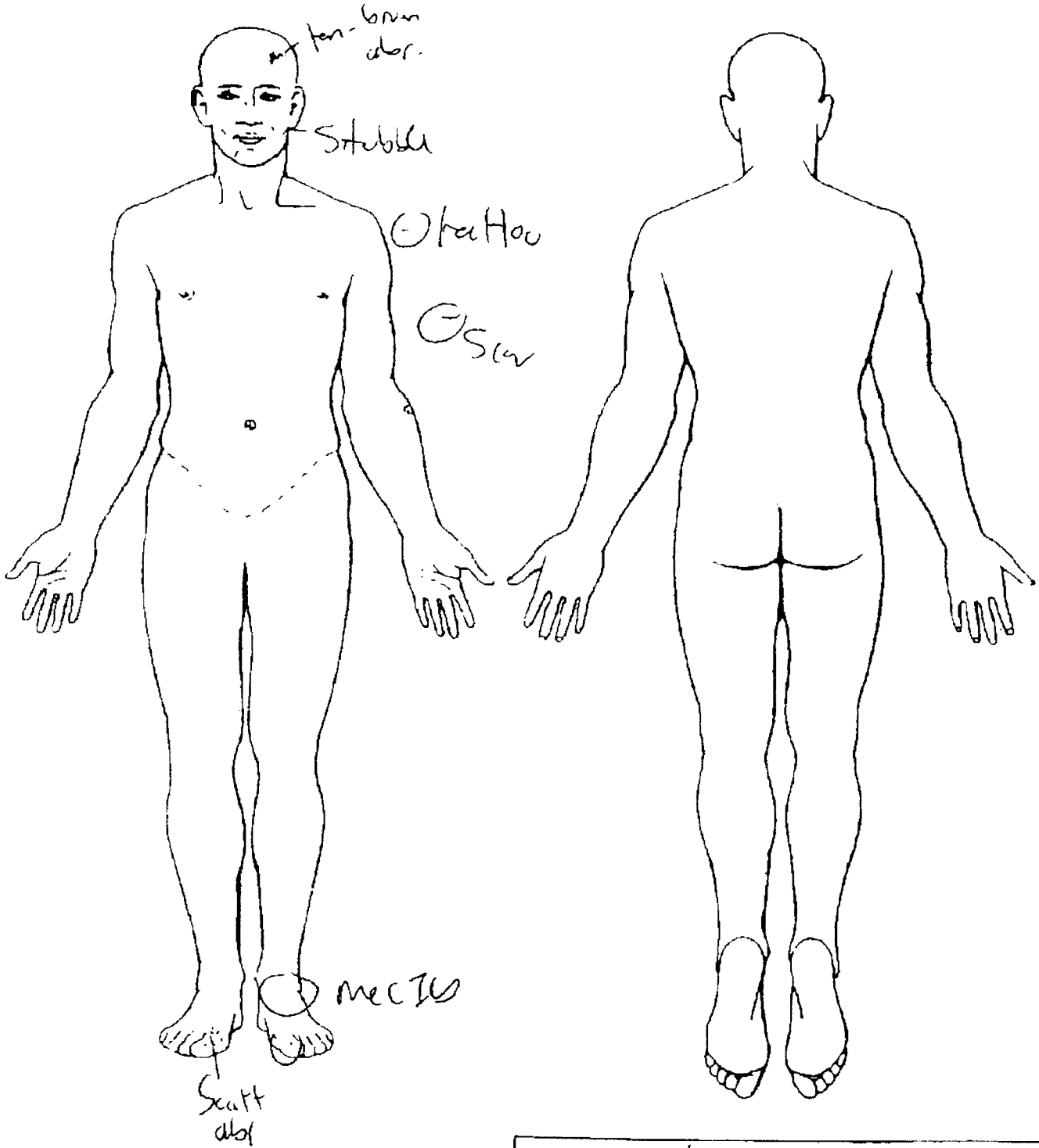
hair: Short gray, stubble  
eyes: hazel lens  
teeth: rat ugly

2022-10791

BRIGNOLE, DOUGLAS

NAT

314



Date 10/14/22

  
 Deputy Medical Examiner M.D.

1	APPARENT MODE <b>NATURAL</b>	CASE NO 2022-10791
	SPECIAL CIRCUMSTANCES	CR/PT 314

LAST, FIRST MIDDLE  
**BRIGNOLE, DOUGLAS PAUL**

AKA #

ADDRESS  
1421 S. SHERBOURNE DRIVE

CITY  
LOS ANGELES

STATE  
CA

ZIP  
90035

SEX  
MALE

RACE APPEARS  
CAUCASIAN

DOB  
12 15 1959

AGE  
62

HGT  
68 in

WGT  
185 lbs

EYES  
BROWN

HAIR  
BROWN

TEETH  
ALL NATURAL

FACIAL HAIR  
UNSHAVEN

ID VIEW  
Yes

CONDITION  
FAIR

MARK TYPE MARK LOCATION MARK DESCRIPTION

D METHOD  
FINGERPRINTS FROM DOJ

IDENTIFIED BY NAME (PRINT)	RELATIONSHIP	PHONE	DATE	TIME
DOJ, FBI, LASD FINGERPRINTS			10/13/2022	16:48

PLACE OF DEATH / PLACE FOUND	ADDRESS OR LOCATION	CITY	ZIP
RESIDENCE	1421 S. SHERBOURNE DRIVE	LOS ANGELES	90035

PLACE OF INJURY	AT WORK	DATE	TIME	LOCATION OR ADDRESS	ZIP
	No				

DOD  
10/13/2022

TIME  
09:25

FOUND OR PRONOUNCED BY  
LAFD RA 58, MATCHENEY

OTHER AGENCY INV OFFICER  
LAPD WEST LOS ANGELES - REZEKALLA & GLAN (310) 440-0701

TRANSPORTED BY

REPORT NO  
22101300001306

NOTIFIED BY

NO

TO  
LOS ANGELES FSC

DATE

TIME

FINGERPRINTS?	No	CLOTHING	Yes	PARPT	No	MORTUARY	
MED EV	No	INVEST PHOTO #	52	SEAL TYPE	CORONER SEAL	HOSP RPT	No
PHYS EV	No	EVIDENCE LOG	No	PROPERTY?	Yes	HOSP CHART	No
SUICIDE NOTE	No	GSR NO		RCPT NO	338596	PT NO	

SYNOPSIS

- FORM 1 ONLY+ ACCORDING TO THE REPORTED INFORMATION, ON 10/13/22 AROUND 0900 HOURS, THE DECEDENT'S HOUSEKEEPER WENT TO THE DECEDENT'S APARTMENT FOR A SCHEDULED APPOINTMENT. SHE ENTERED THE HOME AND FOUND THE DECEDENT LYING PRONE ON THE FLOOR UNRESPONSIVE AND CALLED 911. SHE ALSO WENT TO GET THE DECEDENT'S NEIGHBOR FOR HELP. PER THE 911 OPERATOR, THE HOUSEKEEPER AND THE DECEDENT'S NEIGHBOR TURNED THE DECEDENT ONTO HIS BACK. LAFD RA 58 THEN RESPONDED AND PARAMEDIC MATCHENEY PRONOUNCED DEATH AT 0925 HOURS WITH NO MEDICAL INTERVENTION. THE DECEDENT WAS LAST SEEN ALIVE ON 10/10/22 BY A NEIGHBOR. PER THE DECEDENT'S DOCTOR, HE HAD A HISTORY OF HYPERLIPIDEMIA, ADD, HYPOGONADISM, AND UNSPECIFIED CARDIAC ISSUES. IT IS BELIEVED HE LAST SAW HIS DOCTOR WITHIN THE PAST 6 MONTHS. FAMILY REPORTED THE DECEDENT HAD NO HISTORY OF ALCOHOL ABUSE OR ILLICIT DRUG USE. PER A FRIEND, THE DECEDENT WAS A COMPETITIVE BODY BUILDER AND WAS KNOWN TO USE STEROIDS OCCASIONALLY. THE FRIEND ALSO MENTIONED THE DECEDENT HAD RECENTLY TRAVELLED TO ATLANTIC CITY FOR A COMPETITION AND BECAME SICK WITH A FLU AROUND 10/8/22. MULTIPLE PACKS OF OVER THE COUNTER COLD/FLU MEDICATIONS WERE FOUND ON SCENE. AN EXTERNAL EXAMINATION OF THE DECEDENT ON SCENE REVEALED NO OBVIOUS SIGNS OF TRAUMA. ANT ACTIVITY WAS OBSERVED TO HIS FACE. HE WAS ALSO NOTED TO BE INCONTINENT. FOUL PLAY IS NOT SUSPECTED.

JUSTINE EPPERSON  
643074

*J. Epper*  
INVESTIGATOR

DATE  
10/13/2022

TIME  
18:34

REVIEWED BY

*ATAPL*

DATE  
10/13/22

TIME  
2042

FORM #3 NARRATIVE TO FOLLOW?